Reading an athlete's ECG: from ESC to Seattle and beyond

Domenico Corrado, MD, PhD

Inherited Arrhytmogenic Cardiomyopathy Unit

Department of Cardiac, Thoracic and Vascular Sciences, University of Padova, Italy

domenico.corrado@unipd.it

1st International course in Sports Cardiology

St George's University of London, UK- August 28, 2015

ECG abnormalities in the athlete

- ECG changes in athletes are common and usually reflect morphofunctional remodelling of the heart as an adaptation to regular physical training (athlete's heart).
- However, rarely abnormalities of athlete's ECG may be an expression of an underlying heart disease at risk of sudden arrhythmic death during sport.
- It is imperative that ECG abnormalities resulting from intensive physical training and those potentially associated with an increased cardiovascular risk are properly defined.

The New England
Journal of Medicine

© Copyright, 1998, by the Massachusetts Medical Society

VOLUME 339 AUGUST 6, 1998 NUMBER 6

SCREENING FOR HYPERTROPHIC CARDIOMYOPATHY IN YOUNG ATHLETES

DOMENICO CORRADO, M.D., CRISTINA BASSO, M.D., MAURIZIO SCHIAVON, M.D., AND GAETANO THIENE, M.D.

TABLE 1. CRITERIA FOR A POSITIVE 12-LEAD ELECTROCARDIOGRAM.*

P wave

Left atrial enlargement: negative portion of the P wave in lead V_1 ≥0.1 mV in depth and ≥0.04 sec in duration
Right atrial enlargement: peaked P wave in leads II and III or V_1 ≥0.25 mV in amplitude

QRS complex

Frontal-plane axis deviation: right ≥+120 degrees or left −30 degrees to −90 degrees
Increased voltage: amplitude of R or S wave in a standard lead ≥2 mV, S wave in lead V_1 or V_2 ≥3 mV, or R wave in lead V_5 or V_6 ≥3 mV
Abnormal Q waves ≥0.04 sec in duration or ≥25 percent of the height of the ensuing R wave, or QS pattern in two or more leads
Right or left bundle-branch block with QRS duration ≥0.12 sec
R or R′ wave in lead V_1 ≥0.5 mV in amplitude and R:S ratio ≥1

ST segment, T waves, and QT interval

ST-segment depression or T-wave flattening or inversion in two or more leads
Prolongation of QT interval corrected for the heart rate >0.44 sec

Rhythm and conduction abnormalities

Premature ventricular beats or more severe ventricular arrhythmia
Supraventricular tachycardia, atrial flutter, or atrial fibrillation
Short PR interval (<0.12 sec) with or without delta wave
Sinus bradycardia with resting heart rate ≤40 beats per minute and increasing to <100 beats per minute during limited exercise testing
First-degree (PR ≥0.21 sec, not shortening with hyperventilation or limited exercise testing), second-degree, or third-degree atrioventricular block

*The criteria are from Friedman,[17] Romhilt and Estes,[18] Morris et al.,[19] and Savage et al.[20]

A decade of athlete ECG criteria: Where we've come and where we're going

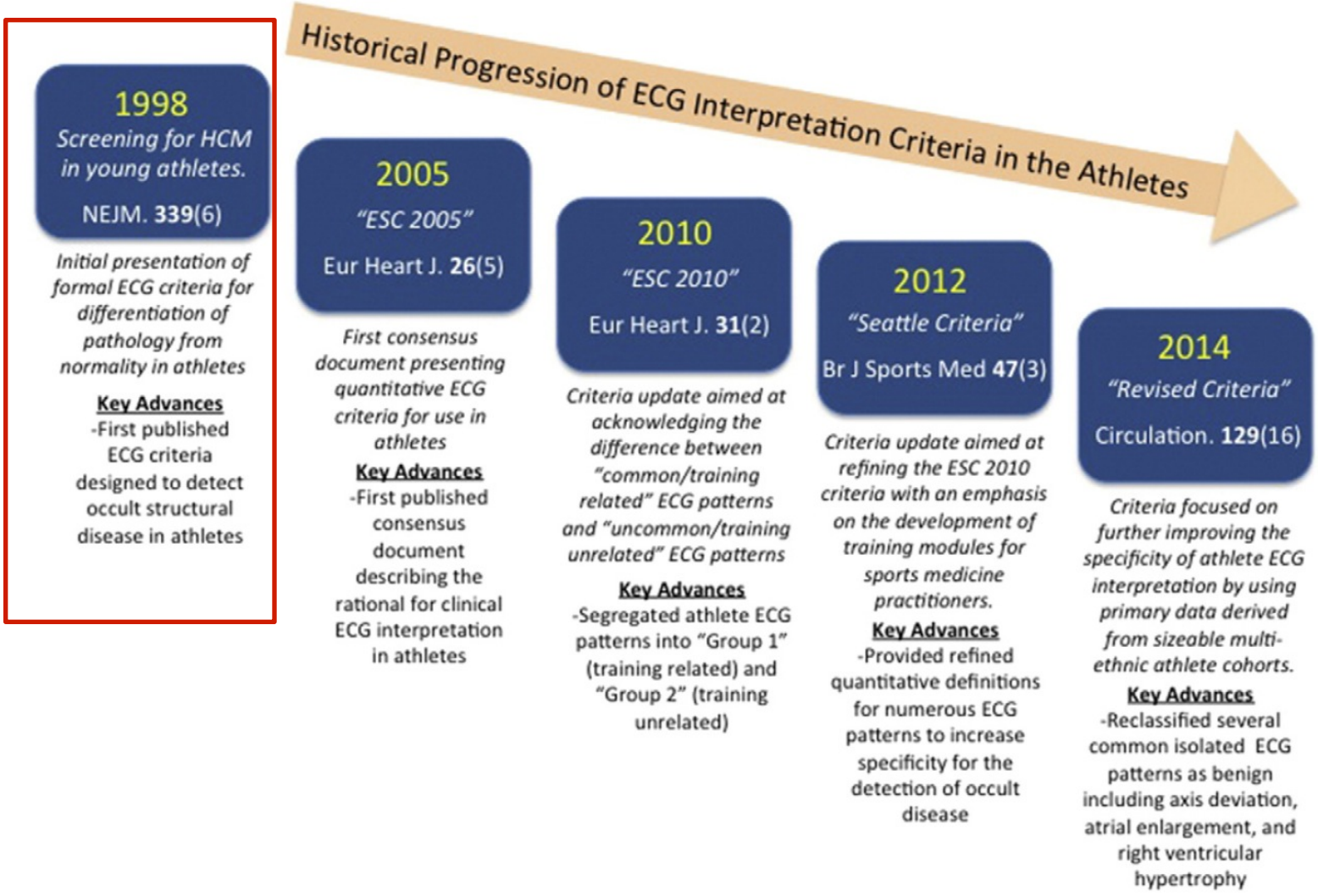

Baggish AL, Journal of Electrocardiology 2015; 48:324–328

A decade of athlete ECG criteria: Where we've come and where we're going

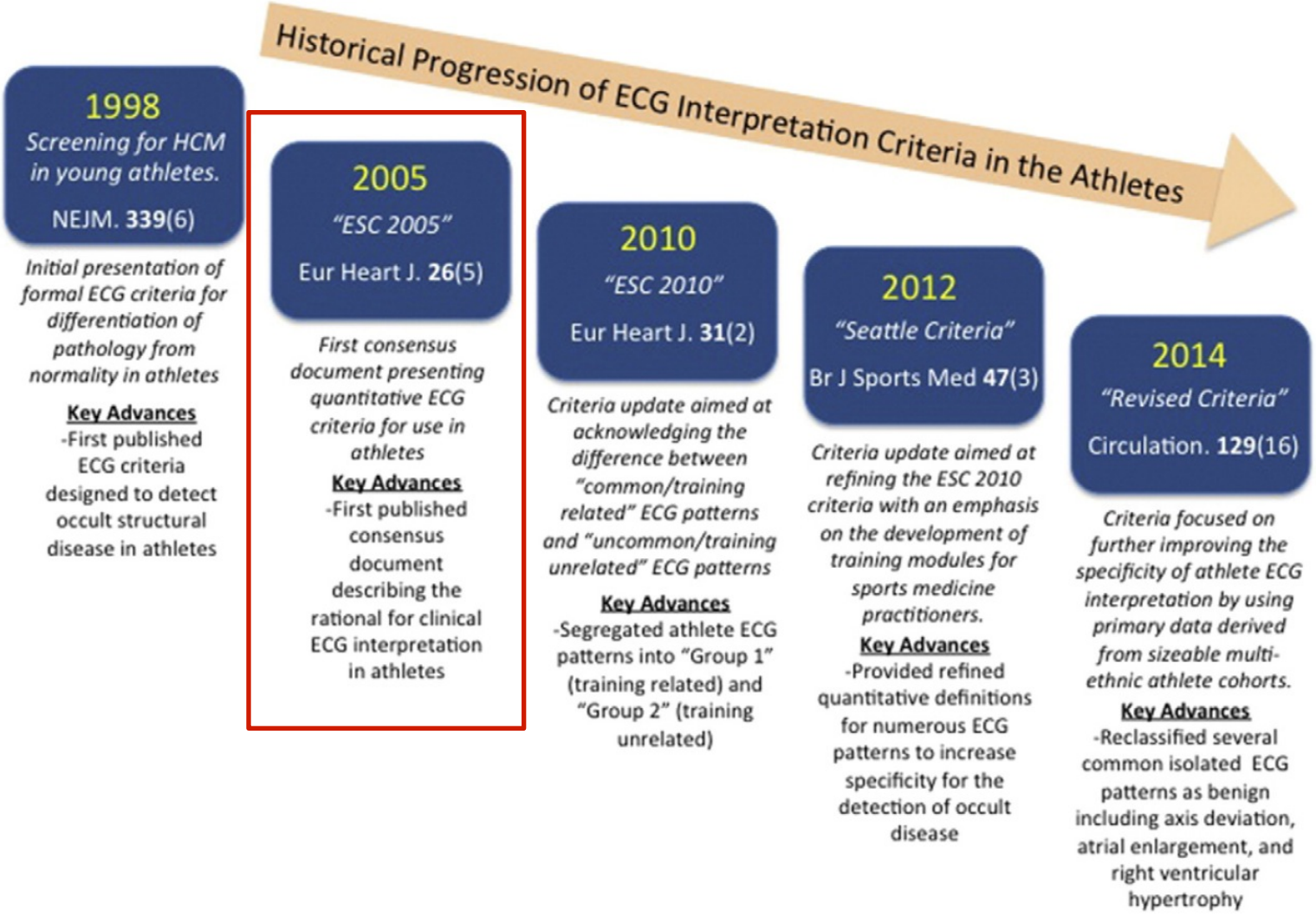

Baggish AL, Journal of Electrocardiology 2015; 48:324–328

European Heart Journal (2005) **26**, 516–524
doi:10.1093/eurheartj/ehi108

EUROPEAN SOCIETY OF CARDIOLOGY®

ESC Report

Cardiovascular pre-participation screening of young competitive athletes for prevention of sudden death: proposal for a common European protocol

Consensus Statement of the Study Group of Sport Cardiology of the Working Group of Cardiac Rehabilitation and Exercise Physiology and the Working Group of Myocardial and Pericardial Diseases of the European Society of Cardiology

Domenico Corrado[1*], Antonio Pelliccia[2], Hans Halvor Bjørnstad[3], Luc Vanhees[4], Alessandro Biffi[2], Mats Borjesson[5], Nicole Panhuyzen-Goedkoop[6], Asterios Deligiannis[7], Erik Solberg[8], Dorian Dugmore[9], Klaus P. Mellwig[10], Deodato Assanelli[11], Pietro Delise[12], Frank van-Buuren[10], Aris Anastasakis[13], Hein Heidbuchel[4], Ellen Hoffmann[14], Robert Fagard[4], Silvia G. Priori[15], Cristina Basso[19], Eloisa Arbustini[16], Carina Blomstrom-Lundqvist[17], William J. McKenna[18], and Gaetano Thiene[19]

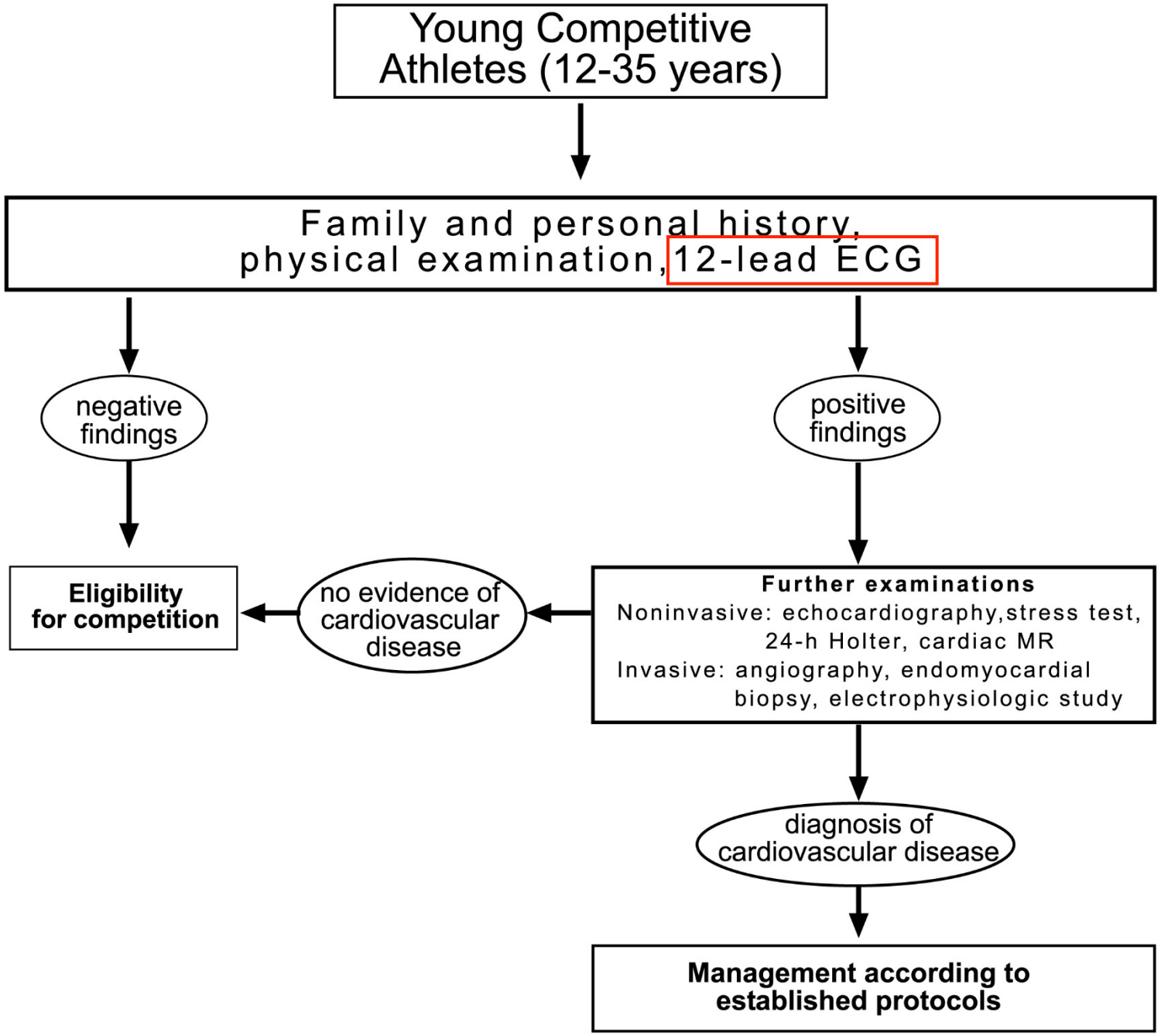
Young Competitive Athletes (12-35 years)
Family and personal history, physical examination, 12-lead ECG
negative findings
positive findings
Eligibility for competition
no evidence of cardiovascular disease
Further examinations
Noninvasive: echocardiography,stress test, 24-h Holter, cardiac MR
Invasive: angiography, endomyocardial biopsy, electrophysiologic study
diagnosis of cardiovascular disease
Management according to established protocols

Table 4 ECG Features of cardiac diseases detectable at pre-participation screening in young competitive athletes

Disease	QTc interval	P wave	PR interval	QRS complex	ST interval	T wave	Arrhythmias
HCM	Normal	(left atrial enlargement)	Normal	Increased voltages in mid-left precordial leads; abnormal Q waves in inferior and/or lateral leads; (LAD, LBBB); (delta wave)	Down-sloping (up-sloping)	Inverted in mid-left precordial leads; (giant and negative in the apical variant)	(Atrial fibrillation); (PVB); (VT)
Arrhythmogenic right ventricular cardiomyopathy/ dysplasia	Normal	Normal	Normal	Prolonged >110 ms in right precordial leads; epsilon wave in right precordial leads; reduced voltages ≤0.5 mV in frontal leads; (RBBB)	(Up-sloping in right precordial leads)	Inverted in right precordial leads	PVB with a LBBB pattern; (VT with a LBBB pattern)
Dilated cardiomyopathy	Normal	(Left atrial enlargement)	(Prolonged ≥0.21 s)	LBBB	Down-sloping (up-sloping)	Inverted in inferior and/or lateral leads	PVB; (VT)
Long QT syndrome	Prolonged >440 ms in males >460 ms in females	Normal	Normal	Normal	Normal	Bifid or biphasic in all leads	(PVB); (torsade de pointes)
Brugada syndrome	Normal		Prolonged ≥0.21 s	S1S2S3 pattern; (RBBB/LAD)	Up-sloping coved-type in right precordial leads	Inverted in right precordial leads	(Polymorphic VT); (atrial fibrillation) (sinus bradycardia)
Lenègre disease	Normal	Normal	Prolonged ≥0.21 s	RBBB; RBBB/LAD; LBBB	Normal	Secondary changes	(2nd or 3rd degree AV block)
Short QT syndrome	Shortened <300 ms	Normal	Normal	Normal	Normal	Normal	Atrial fibrillation (polymorphic VT);
Pre-excitation syndrome (WPW)	Normal	Normal	Shortened <0.12 s	Delta wave	Secondary changes	Secondary changes	Supraventricular tachycardia; (atrial fibrillation)
Coronary artery diseases[a]	(Prolonged)	Normal	Normal	(Abnormal Q waves)[b]	(Down- or up-sloping)	Inverted in ≥2 leads	PVB; (VT);

Less common or uncommon ECG findings are reported in brackets.

QTc: QT interval corrected for heart rate by Bazett's formula. LBBB: left bundle branch block. RBBB: right bundle branch block. LAD: left axis deviation of −30° or more. PVB: either single or coupled premature ventricular beats. VT: either non-sustained or sustained ventricular tachycardia.

[a]Coronary artery diseases: either premature coronary atherosclerosis or congenital coronary anomalies.

[b]Abnormal Q waves (see Table 3).

Corrado et al. Eur Heart J 2005

Trends in Sudden Cardiovascular Death in Young Competitive Athletes After Implementation of a Preparticipation Screening Program

Domenico Corrado, MD, PhD
Cristina Basso, MD, PhD
Andrea Pavei, MD
Pierantonio Michieli, MD, PhD
Maurizio Schiavon, MD
Gaetano Thiene, MD

Context A nationwide systematic preparticipation athletic screening was introduced in Italy in 1982. The impact of such a program on prevention of sudden cardiovascular death in the athlete remains to be determined.

Objective To analyze trends in incidence rates and cardiovascular causes of sudden death in young competitive athletes in relation to preparticipation screening.

Design, Setting, and Participants A population-based study of trends in sudden cardiovascular death in athletic and nonathletic populations aged 12 to 35 years in the Veneto region of Italy between 1979 and 2004. A parallel study examined trends in cardiovascular causes of disqualification from competitive sports in 42 386 athletes undergoing preparticipation screening at the Center for Sports Medicine in Padua (22 312 in the early screening period [1982-1992] and 20 074 in the late screening period [1993-2004]).

THE MAJORITY OF YOUNG ATHLETES who die suddenly have previously unsuspected structural heart disease.[1-8] Cardi-

Corrado et al JAMA 2006;296:1593-1601

Annual Incidence Rates of Sudden Cardiovascular Death in Screened Competitive Athletes and Unscreened Nonathletes Aged 12 to 35 Years in the Veneto Region of Italy (1979-2004)

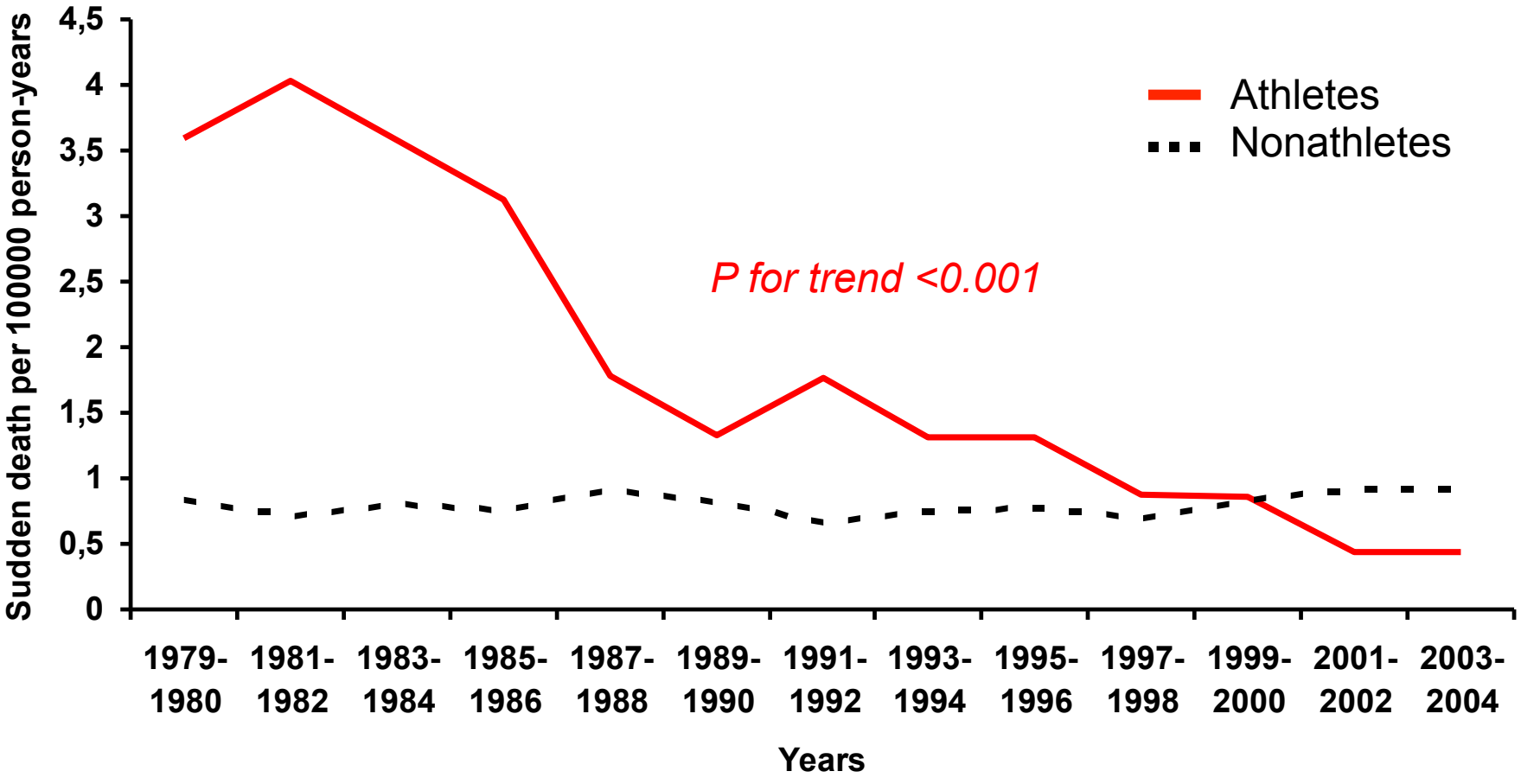

Corrado et al JAMA 2006;296:1593-1601

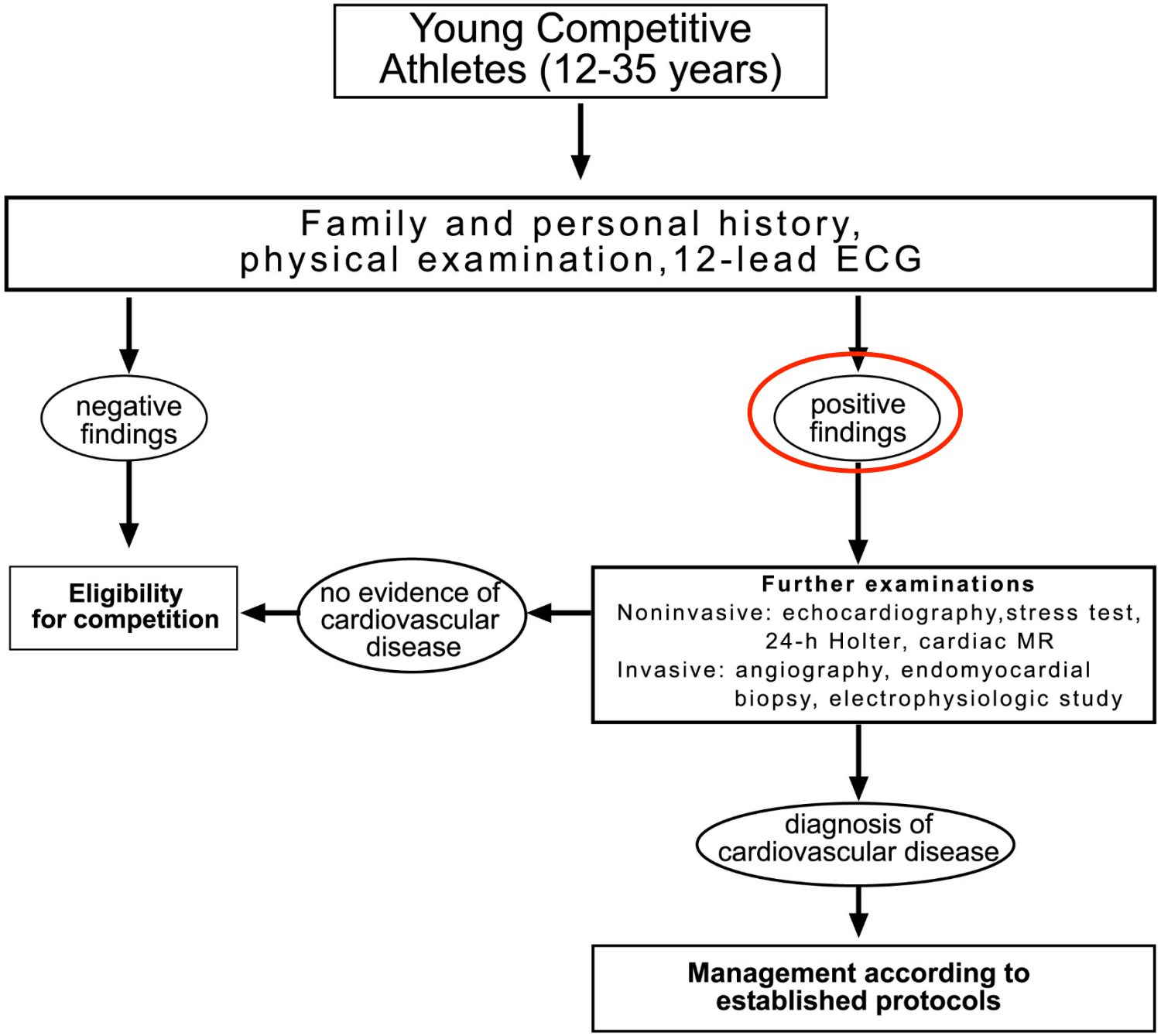
Young Competitive Athletes (12-35 years)
Family and personal history, physical examination,12-lead ECG
negative findings
positive findings
Eligibility for competition
no evidence of cardiovascular disease
Further examinations
Noninvasive: echocardiography,stress test, 24-h Holter, cardiac MR
Invasive: angiography, endomyocardial biopsy, electrophysiologic study
diagnosis of cardiovascular disease
Management according to established protocols

Screening of young athletes for Cardiovascular diseases
(Center for Sports Medicine, Padua 1979-2004)

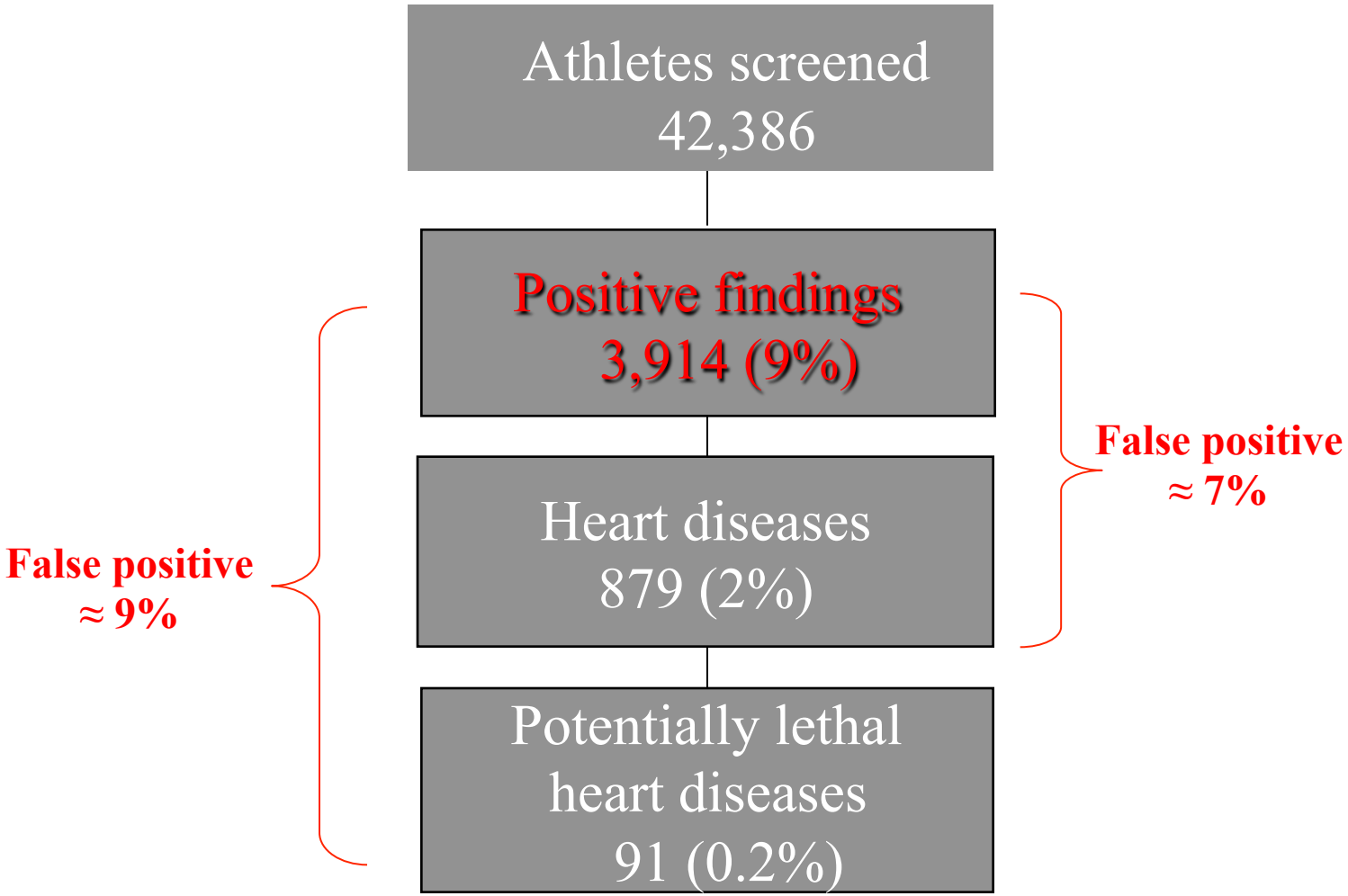

Corrado et al JAMA 2006; 296: 1593-1601

A decade of athlete ECG criteria: Where we've come and where we're going

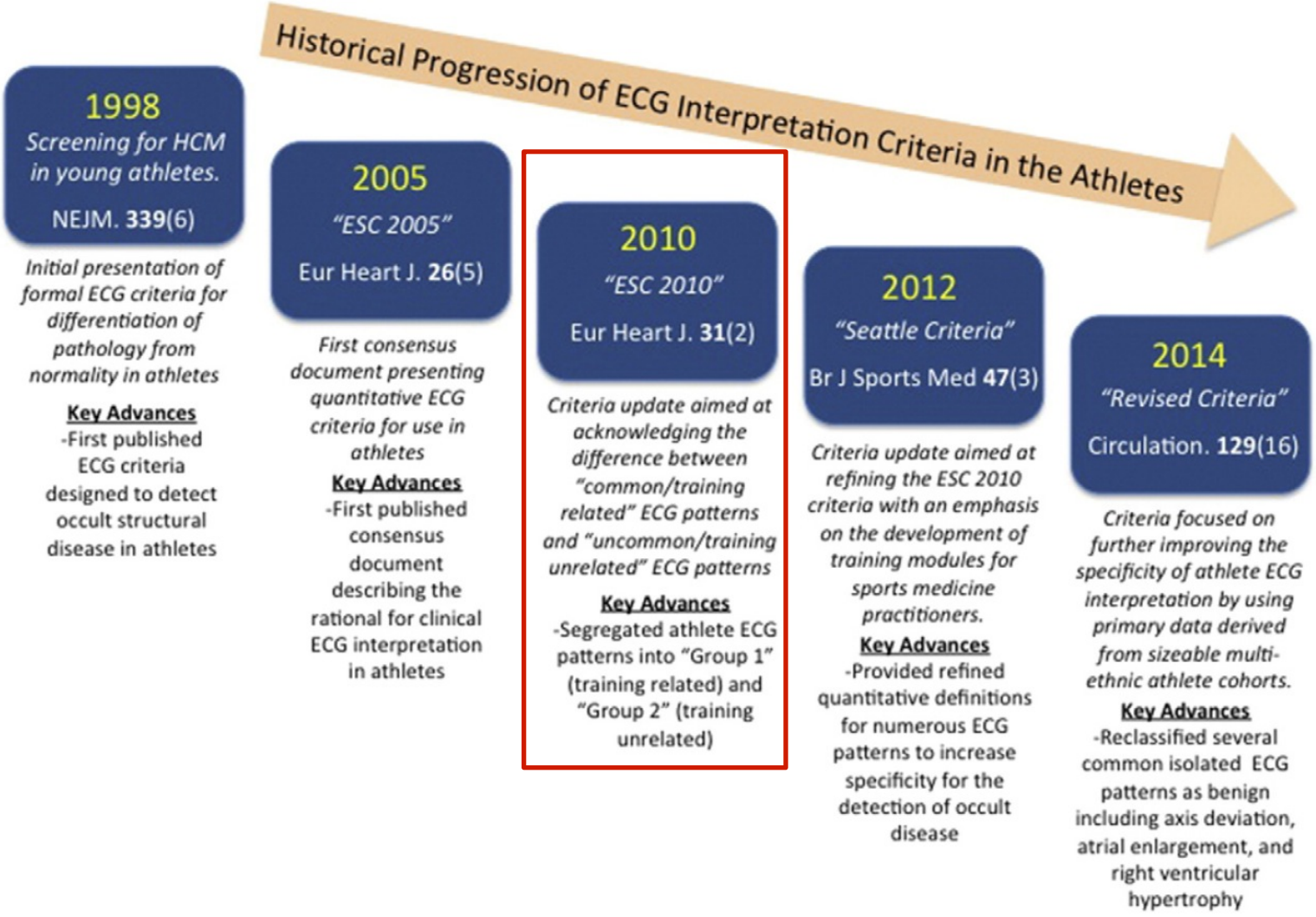

Baggish AL, Journal of Electrocardiology 2015; 48:324–328

EUROPEAN SOCIETY OF CARDIOLOGY®

European Heart Journal (2010) **31**, 243–259
doi:10.1093/eurheartj/ehp473

ESC REPORT

Recommendations for interpretation of 12-lead electrocardiogram in the athlete

Domenico Corrado[1]*, Antonio Pelliccia[2], Hein Heidbuchel[3], Sanjay Sharma[4], Mark Link[5], Cristina Basso[6], Alessandro Biffi[2], Gianfranco Buja[1], Pietro Delise[7], Ihor Gussac[8], Aris Anastasakis[9], Mats Borjesson[10], Hans Halvor Bjørnstad[11], François Carrè[12], Asterios Deligiannis[13], Dorian Dugmore[14], Robert Fagard[3], Jan Hoogsteen[15], Klaus P. Mellwig[16], Nicole Panhuyzen-Goedkoop[17], Erik Solberg[18], Luc Vanhees[3], Jonathan Drezner[19], N.A. Mark Estes, III[5], Sabino Iliceto[1], Barry J. Maron[20], Roberto Peidro[21], Peter J. Schwartz[22], Ricardo Stein[23], Gaetano Thiene[6], Paolo Zeppilli[24], and William J. McKenna[25] on behalf of the Sections of Sports Cardiology of the European Association of Cardiovascular Prevention and Rehabilitation; and the Working Group of Myocardial and Pericardial Disease of the European Society of Cardiology

How to interprete 12-lead ECG in the athlete PERSPECTIVE

- Appropriate interpretation of athlete's ECG requires the distinction of two main groups of abnormalities based on:
  - prevalence,
  - relation to exercise training,
  - inherent cardiovascular risk,
  - and need for further clinical investigation to confirm (or exclude) an underlying cardiovascular disease

Table 1 **Classification of abnormalities of the athlete's electrocardiogram**

Group 1: common and training-related ECG changes	Group 2: uncommon and training-unrelated ECG changes
Sinus bradycardia	T-wave inversion
First-degree AV block	ST-segment depression
Incomplete RBBB	Pathological Q-waves
Early repolarization	Left atrial enlargement
Isolated QRS voltage criteria for left ventricular hypertrophy	Left-axis deviation/left anterior hemiblock
	Right-axis deviation/left posterior hemiblock
	Right ventricular hypertrophy
	Ventricular pre-excitation
	Complete LBBB or RBBB
	Long- or short-QT interval
	Brugada-like early repolarization

RBBB, right bundle branch block; LBBB, left bundle branch block.

Corrado et al. Eur Heart J 2010;31:243–259

Clinical significance of abnormal ECG patterns in trained athletes

TABLE 1. Distribution of ECG Abnormalities in 1005 Trained Athletes

Distinctly Abnormal ECG (n=145)		Mildly Abnormal ECG (n=257)		ECG Normal or With Minor Alterations (n=603)	
Parameter	n (%)	Parameter	n (%)	Parameter	n (%)
R or S wave ≥35 mm	92 (63)	R or S wave 30–34 mm	141 (55)	R or S wave 25–29 mm	170 (28)
Negative T wave	27 (19)	Flat/tall T wave	59 (23)	J-junction elevation	144 (24)
Q wave ≥4 mm	17 (12)	Q wave 2–3 mm	69 (27)	Incomplete RBBB	122 (20)
LAD	11 (8)	LAE	9 (4)	PR interval >0.20 s	75 (12)
RAD	8 (6)	RAE	2 (0.8)		
WPW	3 (2)	Incomplete R wave progression V_1 to V_3	40 (16)	Sinus bradycardia <60 bpm	369 (61)
LBBB	2 (1)	PR interval ≤0.12 s	9 (4)		
		RBBB	2 (0.8)		

J-junction indicates early repolarization pattern; LAD, left axis deviation (≤−30°); LBBB, left bundle branch block; LAE, left atrial enlargement; Incomplete R wave progression V_1 to V_3, abnormal pattern of R wave progression in the anterior precordial leads V_1 to V_3; RAD, right axis deviation (≥110°); RAE, right atrial enlargement; RBBB, right bundle branch block; and WPW, Wolff-Parkinson-White pattern.

Pelliccia et al. Circulation. 2000;102:278-84

Pure increased QRS voltages (Sokolow-Lyon criteria for LVH)

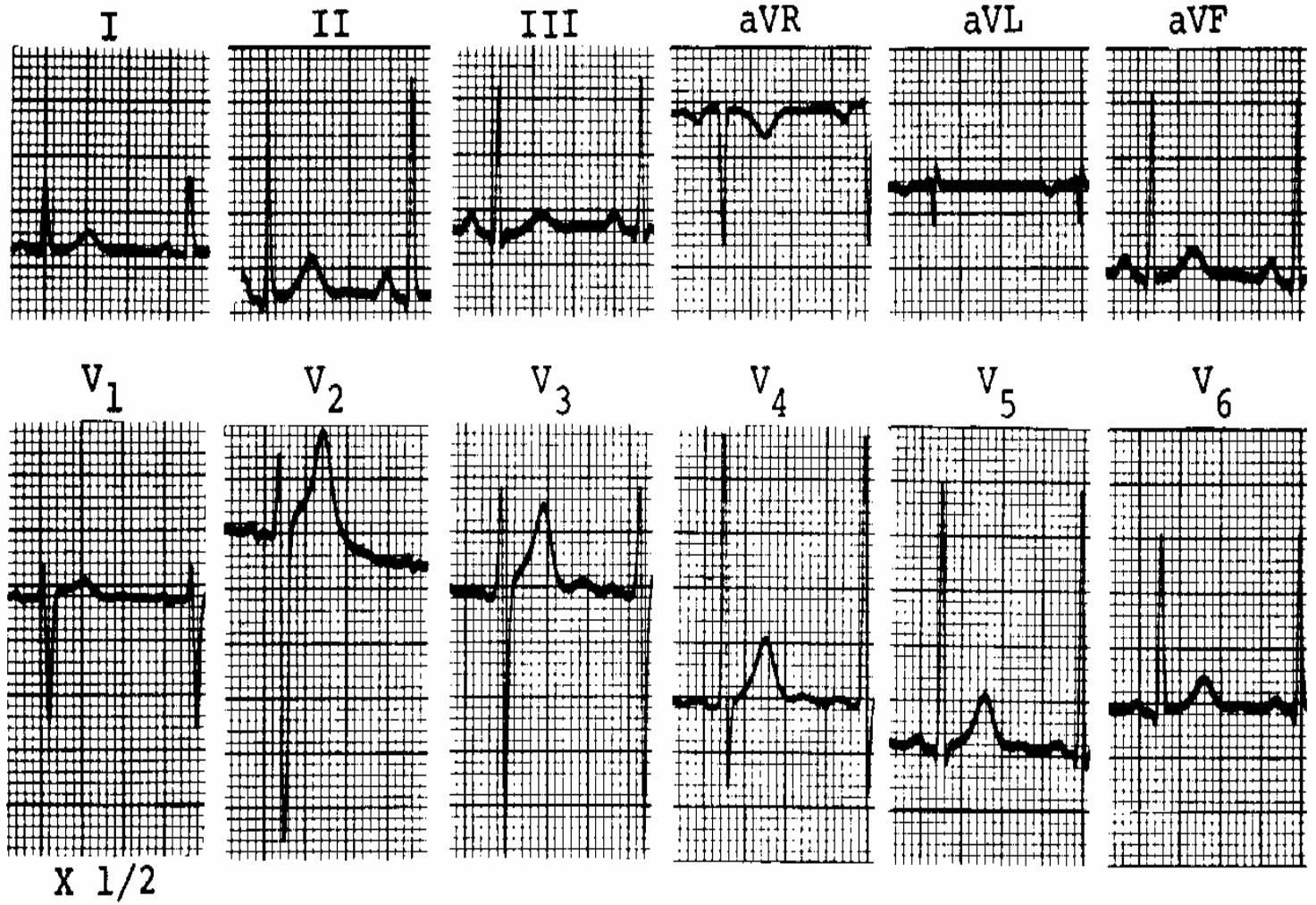

A decade of athlete ECG criteria: Where we've come and where we're going

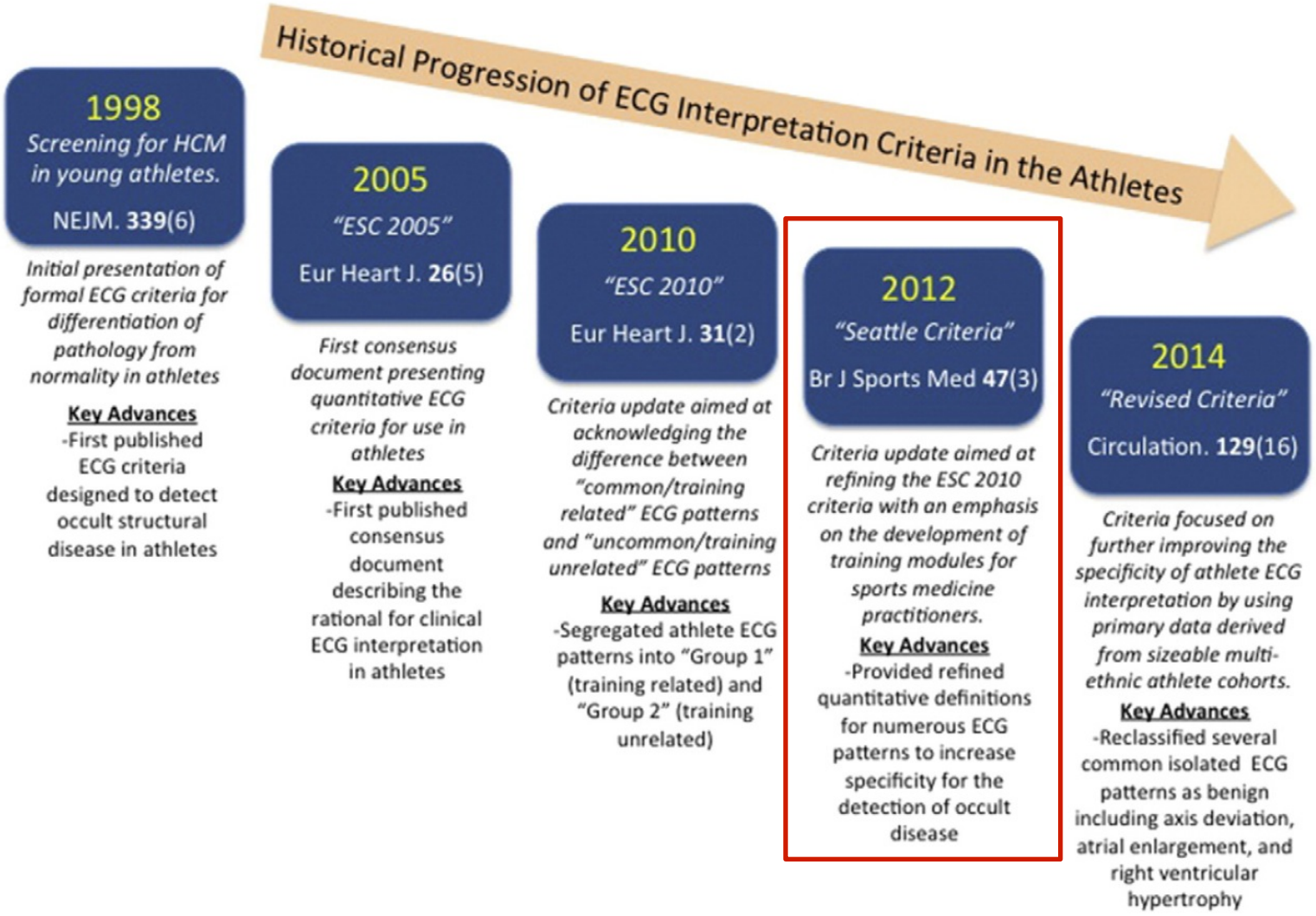

Baggish AL, Journal of Electrocardiology 2015; 48:324–328

EGC interpretation in athletes: the 'Seattle Criteria'

Normal ECG findings in athletes

1. Sinus bradycardia (≥ 30 bpm)
2. Sinus arrhythmia
3. Ectopic atrial rhythm
4. Junctional escape rhythm
5. 1° AV block (PR interval > 200 ms)
6. Mobitz Type I (Wenckebach) 2° AV block
7. Incomplete RBBB
8. Isolated QRS voltage criteria for LVH
   - *Except*: QRS voltage criteria for LVH occurring with any non-voltage criteria for LVH such as left atrial enlargement, left axis deviation, ST segment depression, T-wave inversion or pathological Q waves
9. Early repolarisation (ST elevation, J-point elevation, J-waves or terminal QRS slurring)
10. Convex ('domed') ST segment elevation combined with T-wave inversion in leads V1–V4 in black/African athletes

These common training-related ECG alterations are physiological adaptations to regular exercise, considered normal variants in athletes and do not require further evaluation in asymptomatic athletes.

AV, atrioventricular; bpm, beats per minute; LVH, left ventricular hypertrophy; ms, milliseconds; RBBB, right bundle branch block.

Drezner JA, et al. Br J Sports Med 2013;47:122–124

Abnormal ECG findings in athletes

T-wave inversion	>1 mm in depth in two or more leads V2–V6, II and aVF, or I and aVL (excludes III, aVR and V1)
ST segment depression	≥0.5 mm in depth in two or more leads
Pathologic Q waves	>3 mm in depth or >40 ms in duration in two or more leads (except for III and aVR)
Complete left bundle branch block	QRS ≥120 ms, predominantly negative QRS complex in lead V1 (QS or rS), and upright monophasic R wave in leads I and V6
Intraventricular conduction delay	Any QRS duration ≥140 ms
Left axis deviation	−30° to −90°
Left atrial enlargement	Prolonged P wave duration of >120 ms in leads I or II with negative portion of the P wave ≥1 mm in depth and ≥40 ms in duration in lead V1
Right ventricular hypertrophy pattern	R–V1+S–V5>10.5 mm *AND* right axis deviation >120°
Ventricular pre-excitation	PR interval <120 ms with a delta wave (slurred upstroke in the QRS complex) and wide QRS (>120 ms)
Long QT interval*	QTc≥470 ms (male) QTc≥480 ms (female) QTc>500 ms (marked QT prolongation)
Short QT interval*	QTc≤320 ms
Brugada-like ECG pattern	High take-off and downsloping ST segment elevation followed by a negative T wave in ≥2 leads in V1–V3
Profound sinus bradycardia	<30 BPM or sinus pauses ≥ 3 s
Atrial tachyarrhythmias	Supraventricular tachycardia, atrial-fibrillation, atrial-flutter
Premature ventricular contractions	≥2 PVCs per 10 s tracing
Ventricular arrhythmias	Couplets, triplets and non-sustained ventricular tachycardia

The Seattle Criteria increase the specificity of preparticipation ECG screening among elite athletes

Maria Brosnan,[1,2] Andre La Gerche,[1,2] Jon Kalman,[3] Wilson Lo,[4] Kieran Fallon,[5] Andrew MacIsaac,[1] David Prior[1,2]

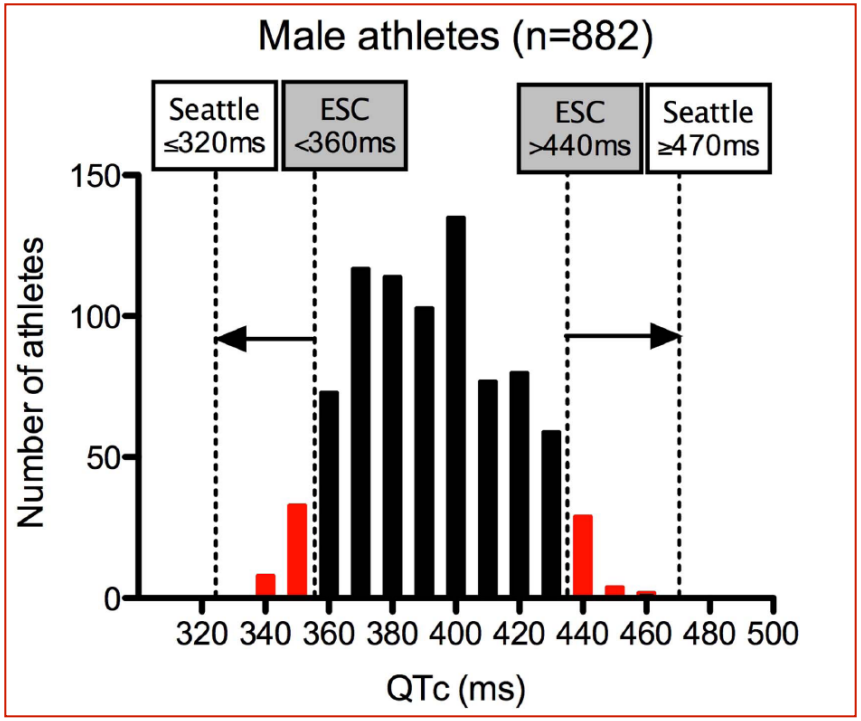

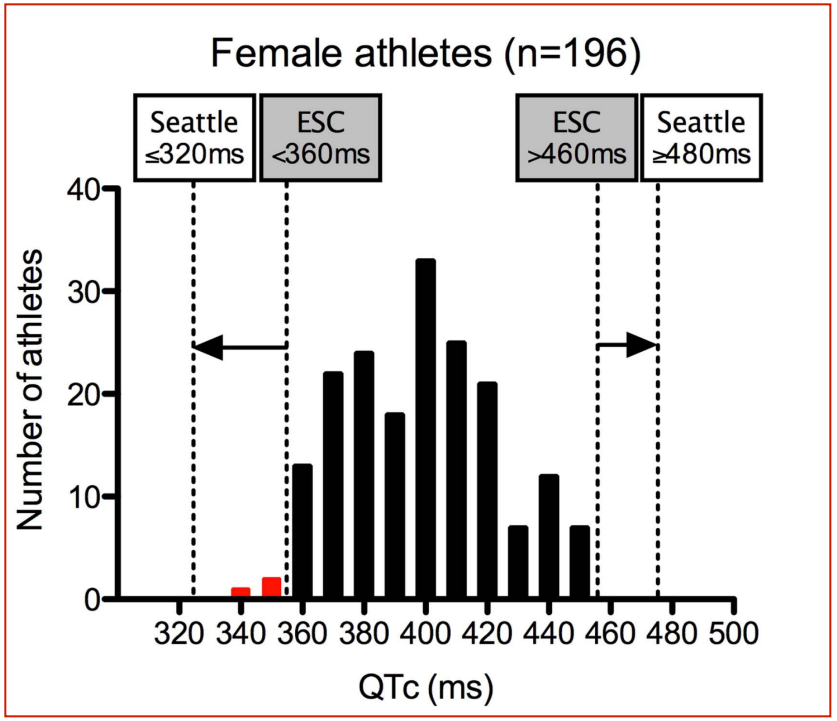

Brosnan et al. Br J Sports Med 2014;48:1144–1150

A decade of athlete ECG criteria: Where we've come and where we're going

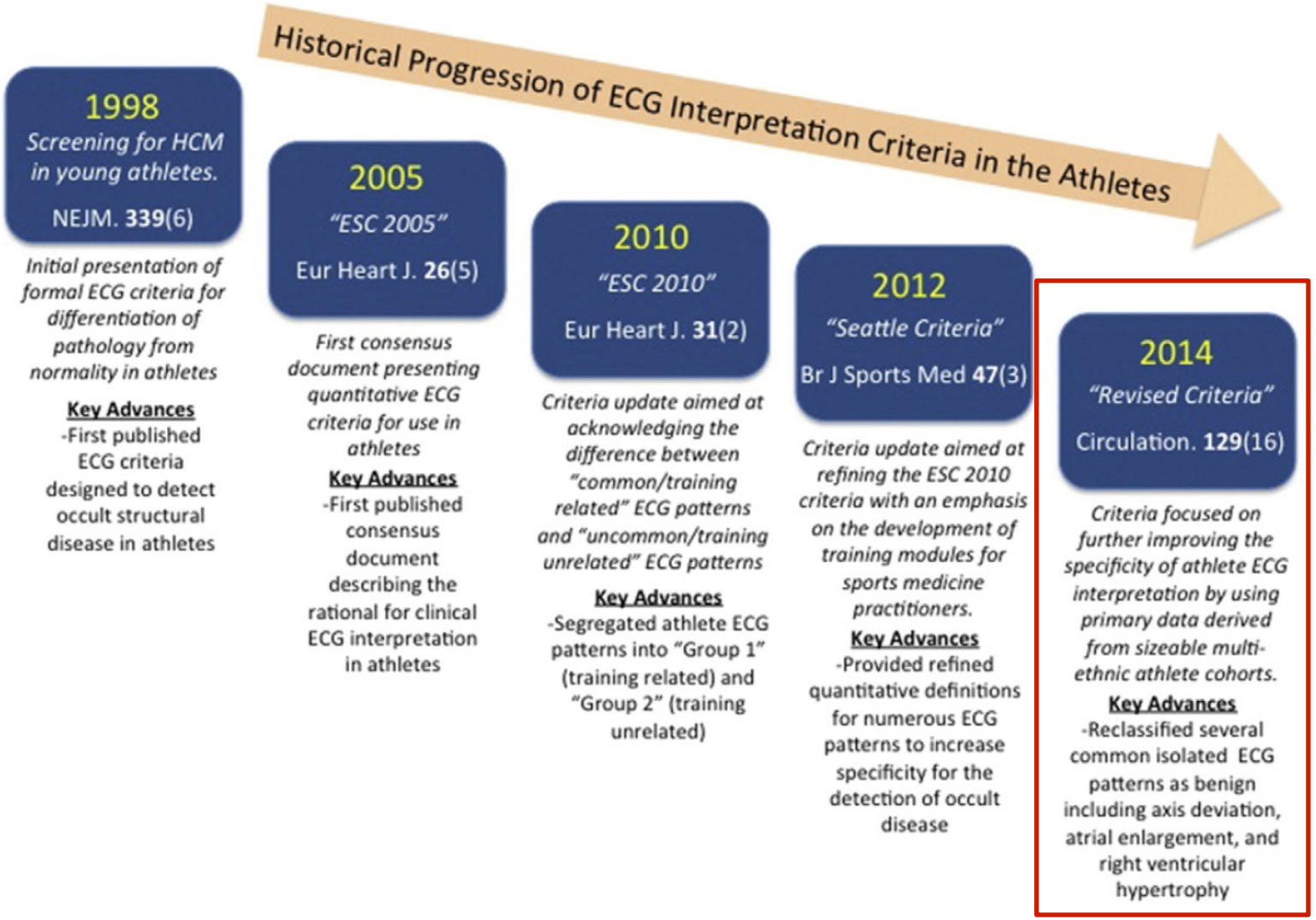

Baggish AL, Journal of Electrocardiology 2015; 48:324–328

CRY refined criteria

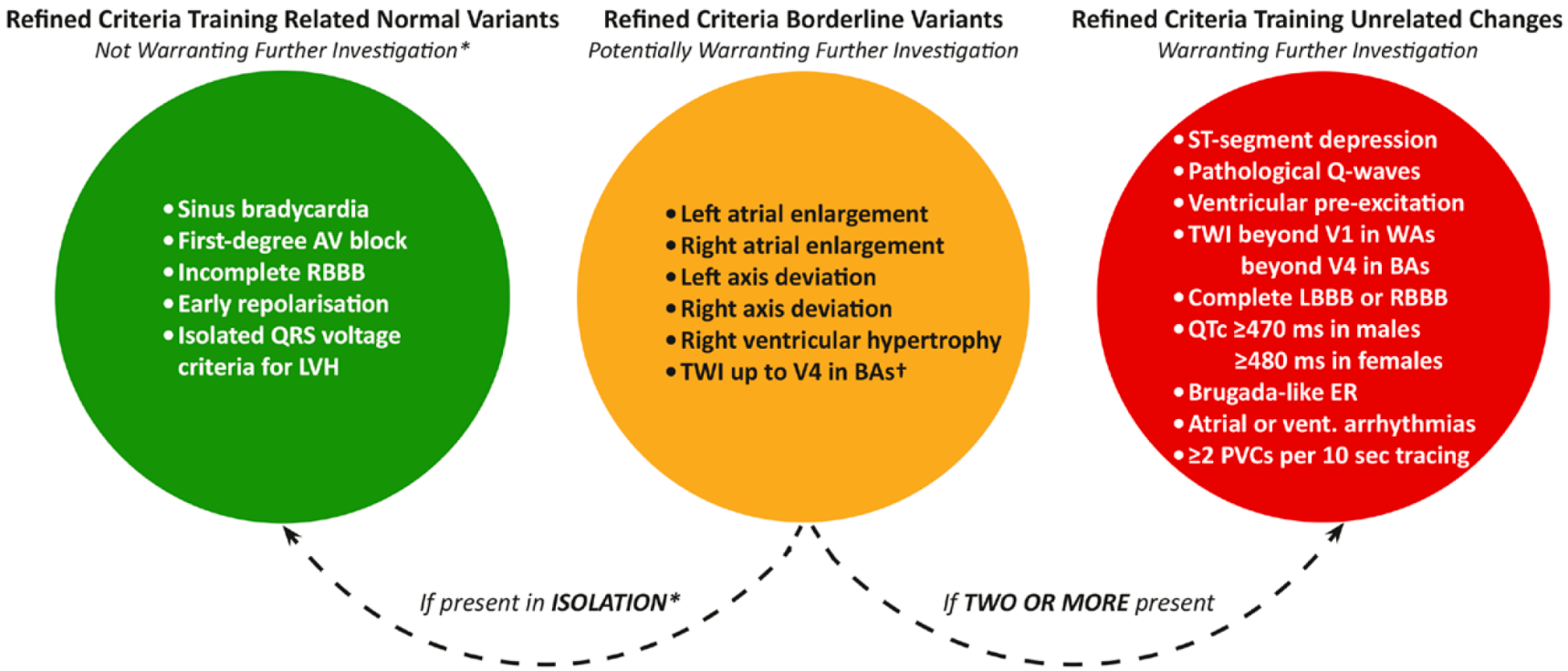

Sheikh et al. Circulation 2014;129:1637-1649

Importance of appropriate interpretation of athlete's ECG

- The importance of distinguishing ECG abnormalities due to the normal athletic heart from heart disease has profound implications.
- Athletes may undergo expensive diagnostic work-up or may be unnecessarily disqualified from competition for abnormalities that fall within the normal range for athletes (specificity).
- Alternatively, signs of potentially lethal cardiovascular disorders may be misinterpreted as normal variants of an athlete's ECG (sensitivity).

Table 1 **Classification of abnormalities of the athlete's electrocardiogram**

Group 1: common and training-related ECG changes	Group 2: uncommon and training-unrelated ECG changes
Sinus bradycardia	T-wave inversion
First-degree AV block	ST-segment depression
Incomplete RBBB	Pathological Q-waves
Early repolarization	Left atrial enlargement
Isolated QRS voltage criteria for left ventricular hypertrophy	Left-axis deviation/left anterior hemiblock
	Right-axis deviation/left posterior hemiblock
	Right ventricular hypertrophy
	Ventricular pre-excitation
	Complete LBBB or RBBB
	Long- or short-QT interval
	Brugada-like early repolarization

RBBB, right bundle branch block; LBBB, left bundle branch block.

Corrado et al. Eur Heart J 2010;31:243–259

Isolated increase of QRS voltages

- According to the ESC recommendation for athlete's ECG interpretation, the ECG changes due to cardiac adaptation to physical exertion, predominantly the physiologic increase of QRS voltages, should not cause alarm and the athlete should be allowed to participate in sports without additional evaluation.
- Although this ECG interpretation approach offers the potential to lower the traditional high number of false positives and to reduce unnecessary and expensive investigations, whether and to what extent the increased specificity alter the ECG sensitivity for HCM remains to be established.

Prevalence and clinical meaning of isolated increase of QRS voltages in hypertrophic cardiomyopathy versus athlete's heart: Relevance to athletic screening ☆

Chiara Calore [a], Paola Melacini [a], Antonio Pelliccia [b], Cinzia Cianfrocca [c], Maurizio Schiavon [d], Fernando M. Di Paolo [b], Francesca Bovolato [a], Filippo M. Quattrini [b], Cristina Basso [a], Gaetano Thiene [a], Sabino Iliceto [a], Domenico Corrado [a,*]

[a] *Department of Cardiac, Thoracic and Vascular Sciences, University of Padua, Italy*
[b] *CONI, Institute of Sports Medicine and Science, Rome, Italy*
[c] *Division of Cardiology, San Filippo Neri Hospital, Rome, Italy*
[d] *Center for Sports Medicine and Physical Activity, Department of Social Health, Padua, Italy*

Table 1
Comparison of ECG findings in HCM and athletes.

ECG	HCM (N = 247)	Athletes (N = 133)	P value
No ECG abnormalities	11 (4)	69 (52)	<0.001
Increased QRS voltage (Sokolow–Lyon)[a] n (%)	90 (36)	59 (44)	0.1
Isolated, n (%)	6/247 (2)	53/133 (40)	<0.001
Associated with non-voltage criteria, n (%)	84/247 (34)	6/133 (4)	<0.001
Left atrial enlargement, n (%)	89 (36)	4 (3)	<0.001
Left axis deviation, n (%)	30 (12)	2 (1)	<0.001
Pathologic Q waves, n (%)	86 (35)	0	<0.001
ST-T alterations, n (%)	202 (82)	6 (4)	<0.001
ST-segment depression, n (%)	164 (66)	0	<0.001
T-wave inversion, n (%)	124 (50)	6 (4)	<0.001
Complete RBBB, n (%)	16 (6)	0	0.003
Complete LBBB, n (%)	11 (4)	0	0.01

HCM = hypertrophic cardiomyopathy; LBBB, left bundle branch block; RBBB, right bundle branch block.
[a] $SV_1 + RV_5$ or RV_6, whichever is larger, >35 mm.

Calore C …Corrado D. Int J Cardiol 2013;168:4494-4497

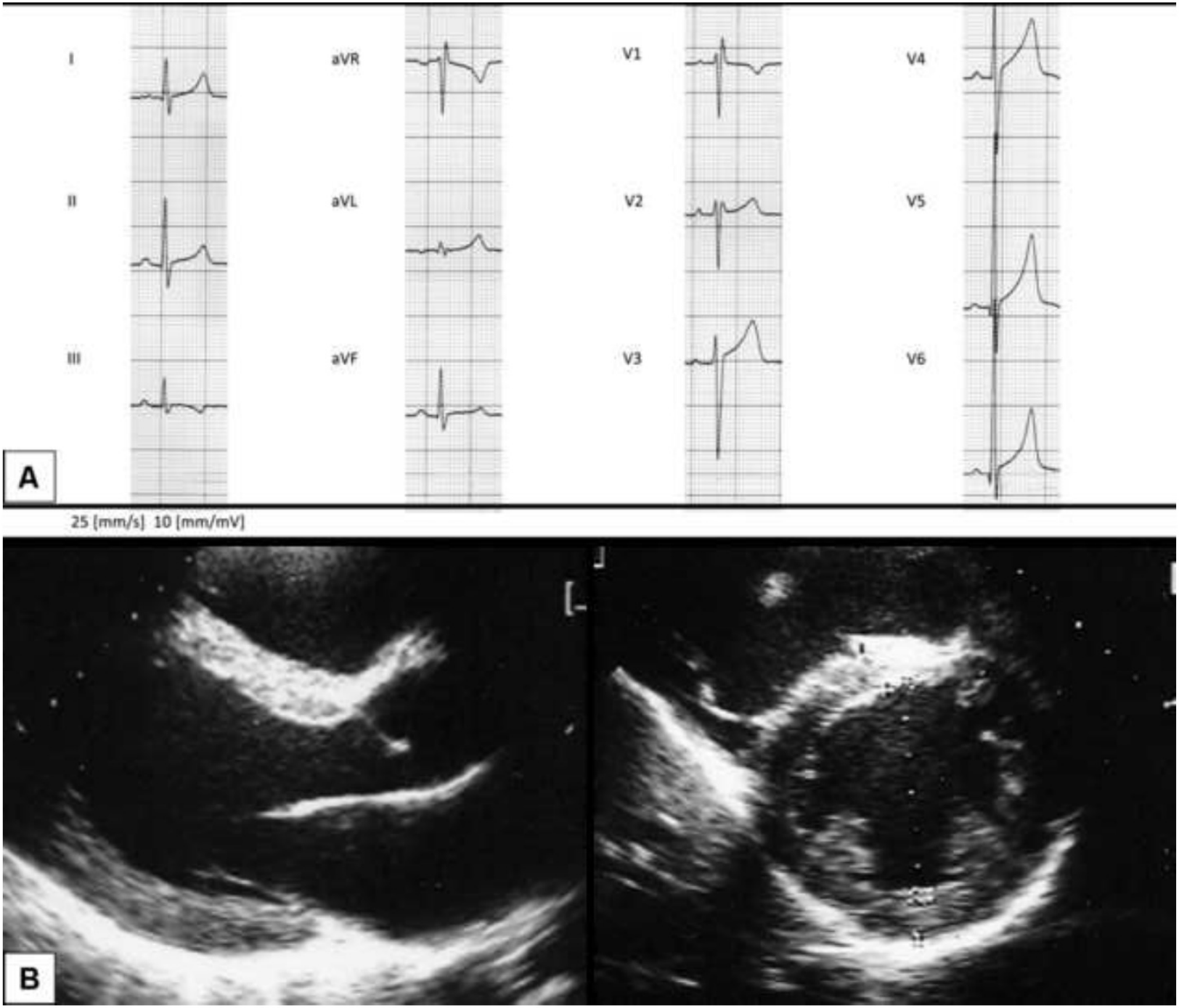
I
aVR
V1
V4
II
aVL
V2
V5
III
aVF
V3
V6
A
25 [mm/s] 10 [mm/mV]
B

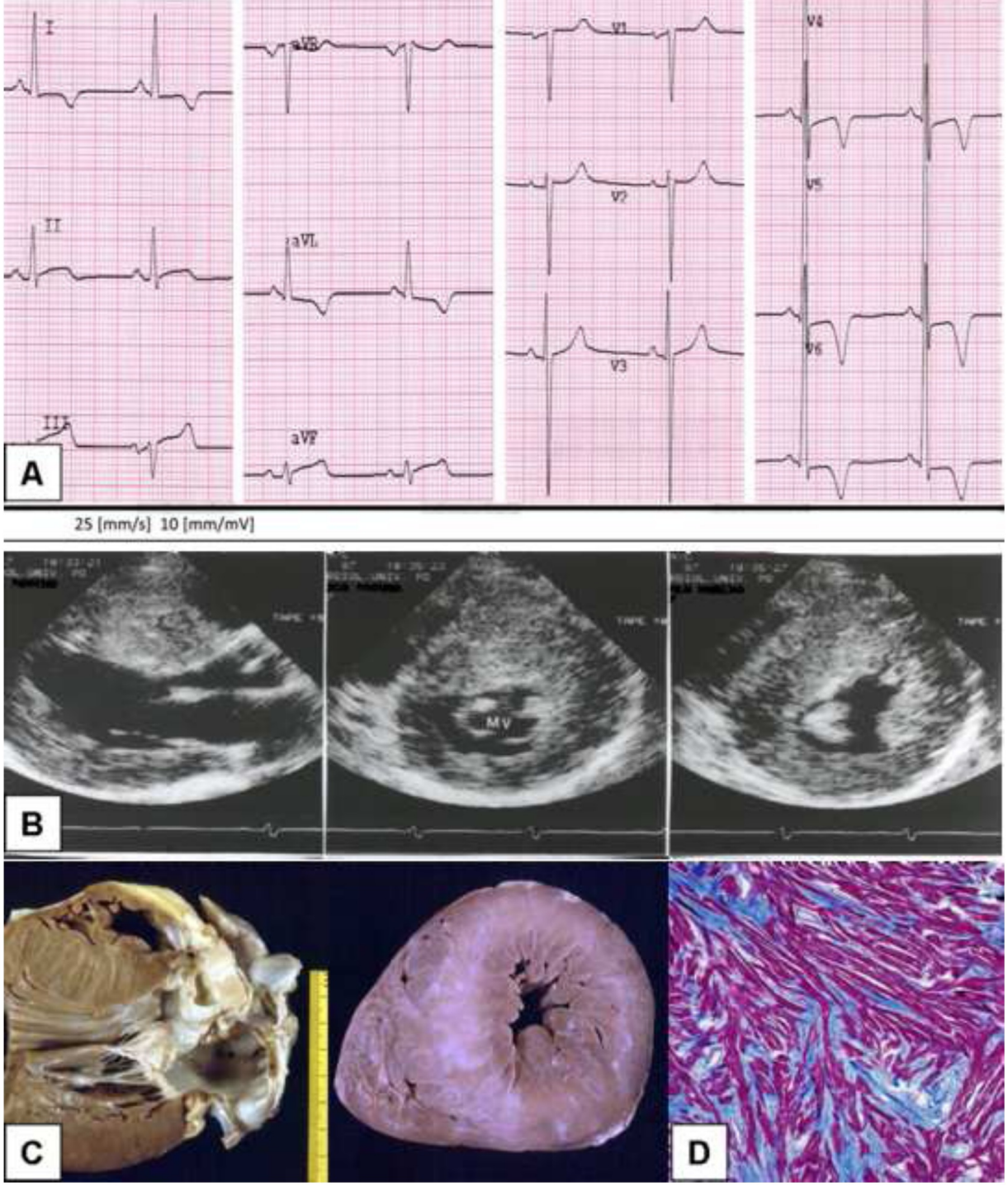
I
II
III
aVR
aVL
aVF
V1
V2
V3
V4
V5
V6
A
25 [mm/s] 10 [mm/mV]
MV
B
C
D

Table 3. Diagnostic value of ECG abnormalities for HCM

ECG abnormality	Sensitivity (%)	Specificity (%)
Group 2 & 3 *	96*	52†
Group 3	93	92

* Group 2: the "isolated increase of QRS voltage group" exhibiting a pure increase of QRS amplitude according to the Sokolow-Lyon criteriona (but no other ECG abnormalities);

Group 3: the "abnormal ECG group" showing ≥1 criteria for atrial enlargement, QRS axis deviation, QRS prolongation, ST-segment or T-wave abnormalities, and abnormal Q wave (regardless of QRS voltages).

Calore C …Corrado D. Int J Cardiol 2013;168:4494-4497

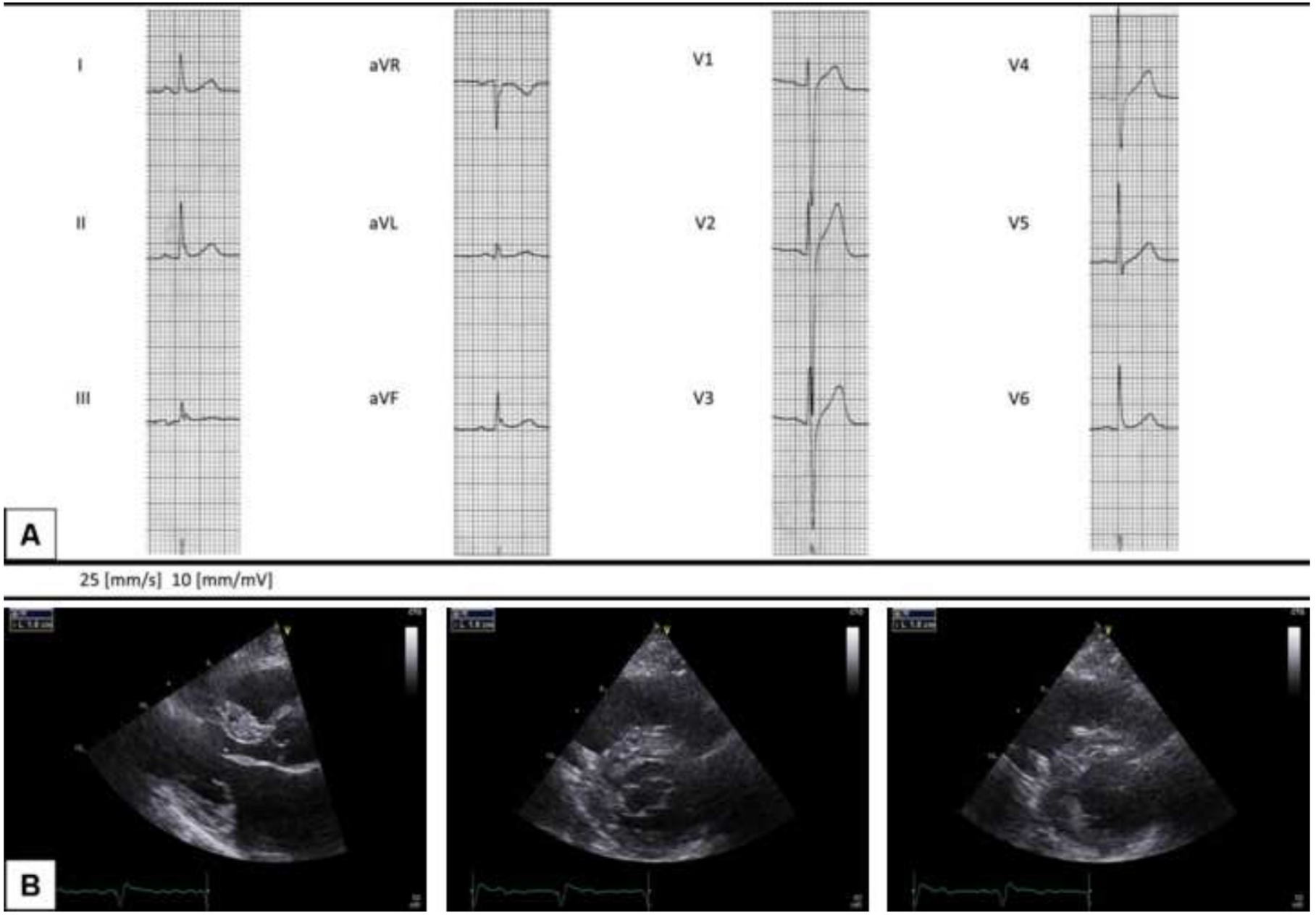
I
aVR
V1
V4
II
aVL
V2
V5
III
aVF
V3
V6
A
25 [mm/s] 10 [mm/mV]
B

Prevalence and clinical meaning of isolated increase of QRS voltages in hypertrophic cardiomyopathy versus athlete's heart: Relevance to athletic screening ☆

Chiara Calore [a], Paola Melacini [a], Antonio Pelliccia [b], Cinzia Cianfrocca [c], Maurizio Schiavon [d], Fernando M. Di Paolo [b], Francesca Bovolato [a], Filippo M. Quattrini [b], Cristina Basso [a], Gaetano Thiene [a], Sabino Iliceto [a], Domenico Corrado [a,*]

[a] Department of Cardiac, Thoracic and Vascular Sciences, University of Padua, Italy
[b] CONI, Institute of Sports Medicine and Science, Rome, Italy
[c] Division of Cardiology, San Filippo Neri Hospital, Rome, Italy
[d] Center for Sports Medicine and Physical Activity, Department of Social Health, Padua, Italy

Table 2
Comparison of clinical characteristics of HCM patients according to ECG group.

Variable	Group 1 (N = 11)	Group 2 (N = 6)	Group 3 (N = 230)	P value*
Age (years)	41 ± 13	37 ± 16	39 ± 17	0.53
Gender (males), n (%)	10 (91)	4 (67)	167 (73)	0.25
Obstruction, n (%)	1 (9)	3 (50)	54 (23)	0.59
Maximal LVWT (mm)	16 ± 2	18 ± 3	21 ± 5	0.01
Mild hypertrophy[a], n (%)	10 (91)	5 (83)	91 (40)	<0.001
LVDD (mm)	47 ± 5	46 ± 4	45 ± 6	0.78
Shortening fraction (%)	45 ± 11	42 ± 5	43 ± 9	0.75
Left atrium diameter (mm)	40 ± 6	43 ± 8	43 ± 8	0.15
Familial HCM, n (%)	5 (45)[b]	1 (17)[b]	82 (36)	0.75
Syncope, n (%)	0	1 (17)	39 (17)	0.16
Major arrhythmic events during follow-up[c], n (%)	0	0	15 (6)	0.30
ICD, n (%)	0	0	31 (17)	0.12

HCM = hypertrophic cardiomyopathy; ICD, implantable cardioverter defibrillator; LVDD, left ventricular end-diastolic dimension; LVWT, left ventricular wall thickness. * P values for the comparison among the three ECG groups to detect differences in mean age, maximal LVWT, LVDD, shortening fraction, left atrium diameter were calculated by one-way analysis of variance (ANOVA). P values for the comparison among the three ECG groups to detect differences in gender, obstruction, proportion of patients with mild hypertrophy, familial HCM, syncope and arrhythmic events (proportions) were calculated by chi-square test or Fisher exact test as appropriate.

[a] Maximal LVWT ≤19 mm.
[b] All relatives identified by family screening.
[c] Sudden cardiac death, cardiac arrest due to ventricular fibrillation, sustained ventricular tachycardia.

Calore C ...Corrado D. Int J Cardiol 2013;168:4494-4497

Table 1 **Classification of abnormalities of the athlete's electrocardiogram**

Group 1: common and training-related ECG changes	Group 2: uncommon and training-unrelated ECG changes
Sinus bradycardia	T-wave inversion
First-degree AV block	ST-segment depression
Incomplete RBBB	Pathological Q-waves
Early repolarization	Left atrial enlargement
Isolated QRS voltage criteria for left ventricular hypertrophy	Left-axis deviation/left anterior hemiblock
	Right-axis deviation/left posterior hemiblock
	Right ventricular hypertrophy
	Ventricular pre-excitation
	Complete LBBB or RBBB
	Long- or short-QT interval
	Brugada-like early repolarization

RBBB, right bundle branch block; LBBB, left bundle branch block.

Corrado et al. Eur Heart J 2010;31:243–259

Cardiovascular causes of sudden death associated with sports

Adults (age > 35 years):

Atherosclerotic coronary artery disease

Young competitive athletes (age ≤35 years):

Hypertrophic cardiomyopathy

Arrhythmogenic right ventricular cardiomyopathy

Congenital anomalies of coronary arteries

Myocarditis

Aortic rupture

Valvular disease

Preexcitation syndromes and conduction diseases

Ion channel diseases

Congenital heart disease, operated or unoperated

Leading causes of sudden cardiovascular death in young competitive athletes

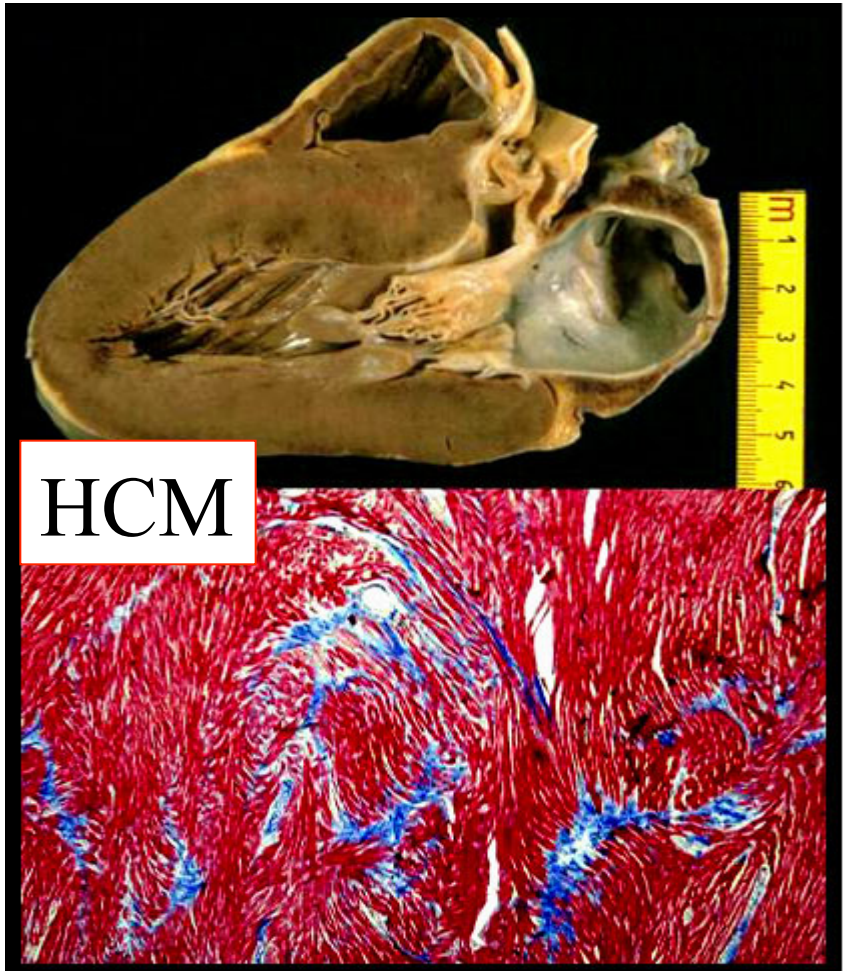

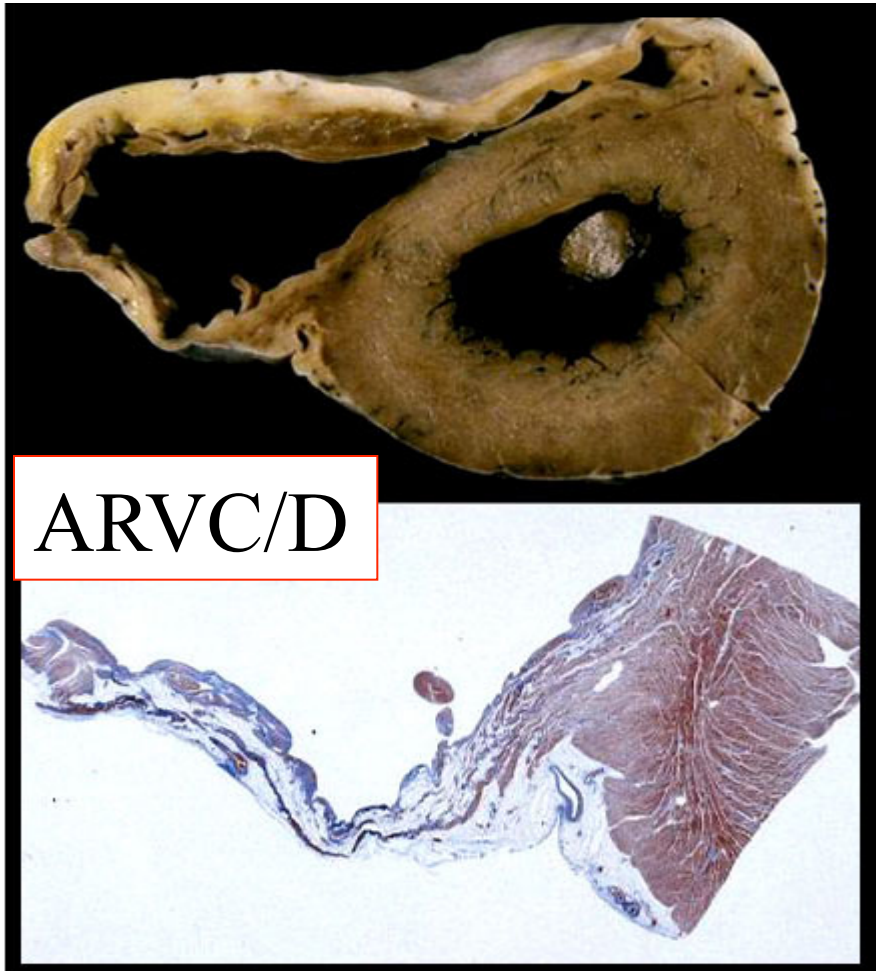

Prevalence of Cardiomyopathy in Italian Asymptomatic Children With Electrocardiographic T-Wave Inversion at Preparticipation Screening

Federico Migliore, MD; Alessandro Zorzi, MD; Pierantonio Michieli, MD, PhD; Martina Perazzolo Marra, MD, PhD; Mariachiara Siciliano, MD; Ilaria Rigato, MD, PhD; Barbara Bauce, MD, PhD; Cristina Basso, MD, PhD; Daniela Toazza, MD; Maurizio Schiavon, MD; Sabino Iliceto, MD; Gaetano Thiene, MD; Domenico Corrado, MD, PhD

Background—T-wave inversion on a 12-lead ECG is usually dismissed in young people as normal persistence of the juvenile pattern of repolarization. However, T-wave inversion is a common ECG abnormality of cardiomyopathies such as hypertrophic cardiomyopathy and arrhythmogenic right ventricular cardiomyopathy, which are leading causes of sudden cardiac death in athletes. We prospectively assessed the prevalence, age relation, and underlying cardiomyopathy of T-wave inversion in children undergoing preparticipation screening.

Methods and Results—The study population included 2765 consecutive Italian children (1914 male participants; mean age, 13.9±2.2 years; range 8–18 years) undergoing preparticipation screening including an ECG. Of 229 children (8%) who underwent further evaluation because of positive findings at initial preparticipation screening, 33 (1.2%) were diagnosed with cardiovascular disease. T-wave inversion was recorded in 158 children (5.7%) and was localized in the right precordial leads in 131 (4.7%). The prevalence of right precordial T-wave inversion decreased significantly with increasing age (8.4% in children <14 years of age versus 1.7% in those ≥14 years; $P<0.001$), pubertal development (9.5% of children with incomplete versus 1.6% with complete development; $P<0.001$), and body mass index below the 10th percentile ($P<0.001$). Incomplete pubertal development was the only independent predictor for right precordial T-wave inversion (odds ratio, 3.6; 95% confidence interval, 1.9–6.8; $P<0.001$). Of 158 children with T-wave inversion, 4 (2.5%) had a diagnosis of cardiomyopathy, including arrhythmogenic right ventricular cardiomyopathy (n=3) and hypertrophic cardiomyopathy (n=1).

Conclusions—The prevalence of T-wave inversion decreases significantly after puberty. Echocardiographic investigation of children with postpubertal persistence of T-wave inversion at preparticipation screening is warranted because it may lead to presymptomatic diagnosis of a cardiomyopathy that could lead to sudden cardiac death during sports. (***Circulation.*** **2012;125:529-538.**)

Key Words: arrhythmogenic right ventricular dysplasia ■ athletes ■ cardiomyopathy, hypertrophic ■ child ■ electrocardiography

Prevalence of right precordial T-wave inversion at preparticipation ECG screening: a prospective study on 2765 asymptomatic children

- Study population: 2765 consecutive children
- Gender: 1914 M (70%)
- Age: mean 13.9±2.2 yrs; median, 14 years; range 8-18 yrs
- T-wave inversion beyond V1(overall): 131 (4.7%)
  - 72 (2.6%) in leads V1 and V2
  - 59 (2.1%) in leads V1 to V3 or beyond
- T-wave inversion (ath.≥14 years): 26/1521 (1.7%)
- T-wave inversion (ath.<14 years): 105/1244 (8.4%)

p<.001

- ARVC/D diagnosis (Echo/cardiac MR): 3 of 131 (2.3%)
- ARVC/D prevalence in this population: 0.1%

Migliore F…Corrado D, Circulation 2012:125:529-538

ECG and echocardiographic findings in a 14-year-old male

Juvenile pattern of repolarization

According to ESC recommendations,

T-wave inversion beyond V1 is seen in post-pubertal athletes less commonly than previously thought (1.5%), but deserves

special consideration because it may reflect underlying ARVC

Table 1 **Classification of abnormalities of the athlete's electrocardiogram**

Group 1: common and training-related ECG changes	Group 2: uncommon and training-unrelated ECG changes
Sinus bradycardia	T-wave inversion
First-degree AV block	ST-segment depression
Incomplete RBBB	Pathological Q-waves
Early repolarization	Left atrial enlargement
Isolated QRS voltage criteria for left ventricular hypertrophy	Left-axis deviation/left anterior hemiblock
	Right-axis deviation/left posterior hemiblock
	Right ventricular hypertrophy
	Ventricular pre-excitation
	Complete LBBB or RBBB
	Long- or short-QT interval
	Brugada-like early repolarization

RBBB, right bundle branch block; LBBB, left bundle branch block.

Corrado et al. Eur Heart J 2010;31:243–259

Right precordial early repolarization

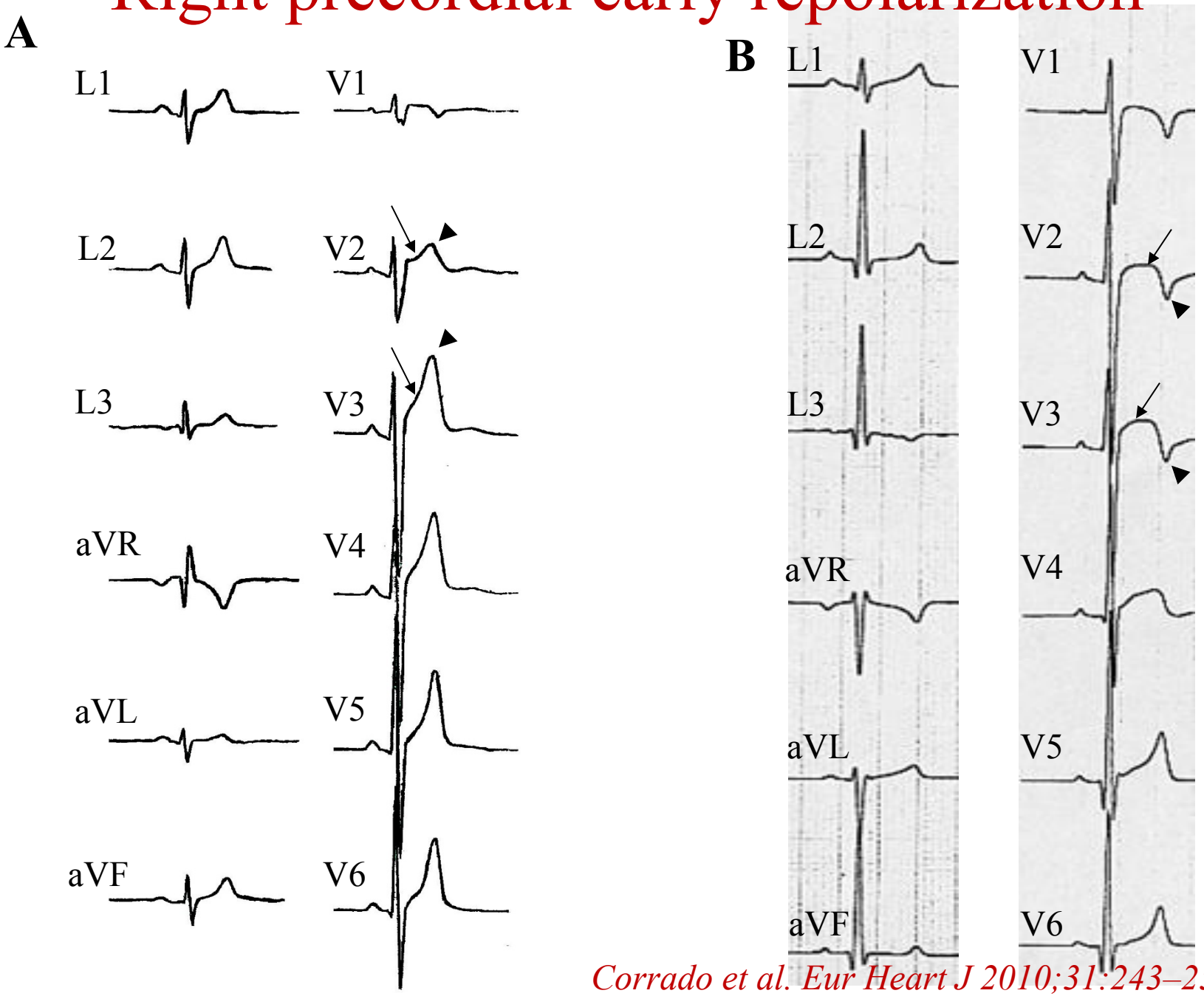

Corrado et al. Eur Heart J 2010;31:243–259

Electrocardiographic interpretation in athletes: the 'Seattle Criteria'

Jonathan A Drezner,[1] Michael John Ackerman,[2] Jeffrey Anderson,[3] Euan Ashley,[4] Chad A Asplund,[5] Aaron L Baggish,[6] Mats Börjesson,[7] Bryan C Cannon,[8] Domenico Corrado,[9] John P DiFiori,[10] Peter Fischbach,[11] Victor Froelicher,[4] Kimberly G Harmon,[1] Hein Heidbuchel,[12] Joseph Marek,[13] David S Owens,[14] Stephen Paul,[15] Antonio Pelliccia,[16] Jordan M Prutkin,[14] Jack C Salerno,[17] Christian M Schmied,[18] Sanjay Sharma,[19] Ricardo Stein,[20] Victoria L Vetter,[21] Mathew G Wilson[22]

Box 1 Normal ECG findings in athletes

1. Sinus bradycardia (≥ 30 bpm)
2. Sinus arrhythmia
3. Ectopic atrial rhythm
4. Junctional escape rhythm
5. 1° AV block (PR interval > 200 ms)
6. Mobitz Type I (Wenckebach) 2° AV block
7. Incomplete RBBB
8. Isolated QRS voltage criteria for LVH
   - *Except*: QRS voltage criteria for LVH occurring with any non-voltage criteria for LVH such as left atrial enlargement, left axis deviation, ST segment depression, T-wave inversion or pathological Q waves
9. Early repolarisation (ST elevation, J-point elevation, J-waves or terminal QRS slurring)
10. Convex ('domed') ST segment elevation combined with T-wave inversion in leads V1–V4 in black/African athletes

Drezner JA, et al. Br J Sports Med 2013;47:122–124

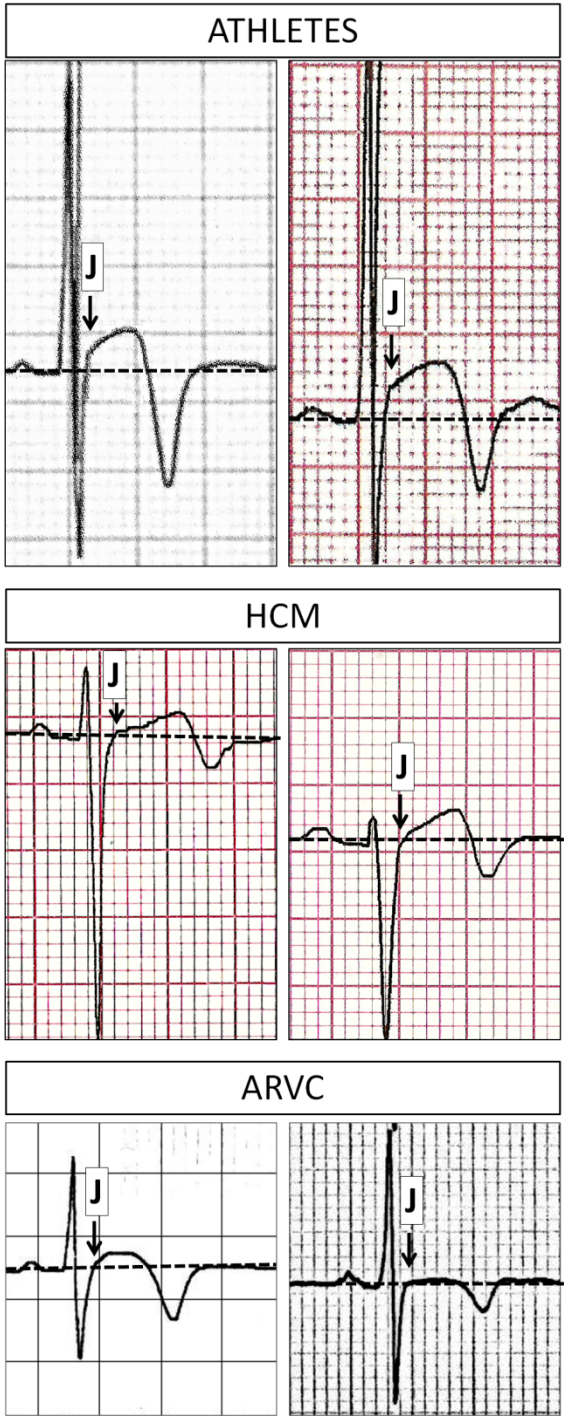

Negative T-waves in V1-V4

(80 athletes, 95 HCM, 58 ARVC)

↓

Negative T-waves extending beyond V4 ? → **YES**

(23 [29%] athletes, 92 [97%] HCM, 32 [55%] ARVC)

↓ **NO**

(57 [71%] athletes, 3 [3%] HCM, 26 [45%] ARVC)

↓

J-point elevation ? → **NO**

(13 [16%] athletes, 3 [3%] HCM, 26 [45%] ARVC)

↓ **YES**

(44 [55%] athletes, 0 HCM, 0 ARVC)

↓

NO further investigations

Further investigations to exclude a cardiomyopathy

Calore C…Corrado D (submitted to Eur Heart J)

Differential Diagnosis Between Early Repolarization of Athlete's Heart and Coved-Type Brugada Electrocardiogram

Alessandro Zorzi, MD[a], Loira Leoni, MD, PhD[a], Fernando M. Di Paolo, MD[b], Ilaria Rigato, MD, PhD[a], Federico Migliore, MD, PhD[a], Barbara Bauce, MD, PhD[a], Antonio Pelliccia, MD[b], and Domenico Corrado, MD, PhD[a,*]

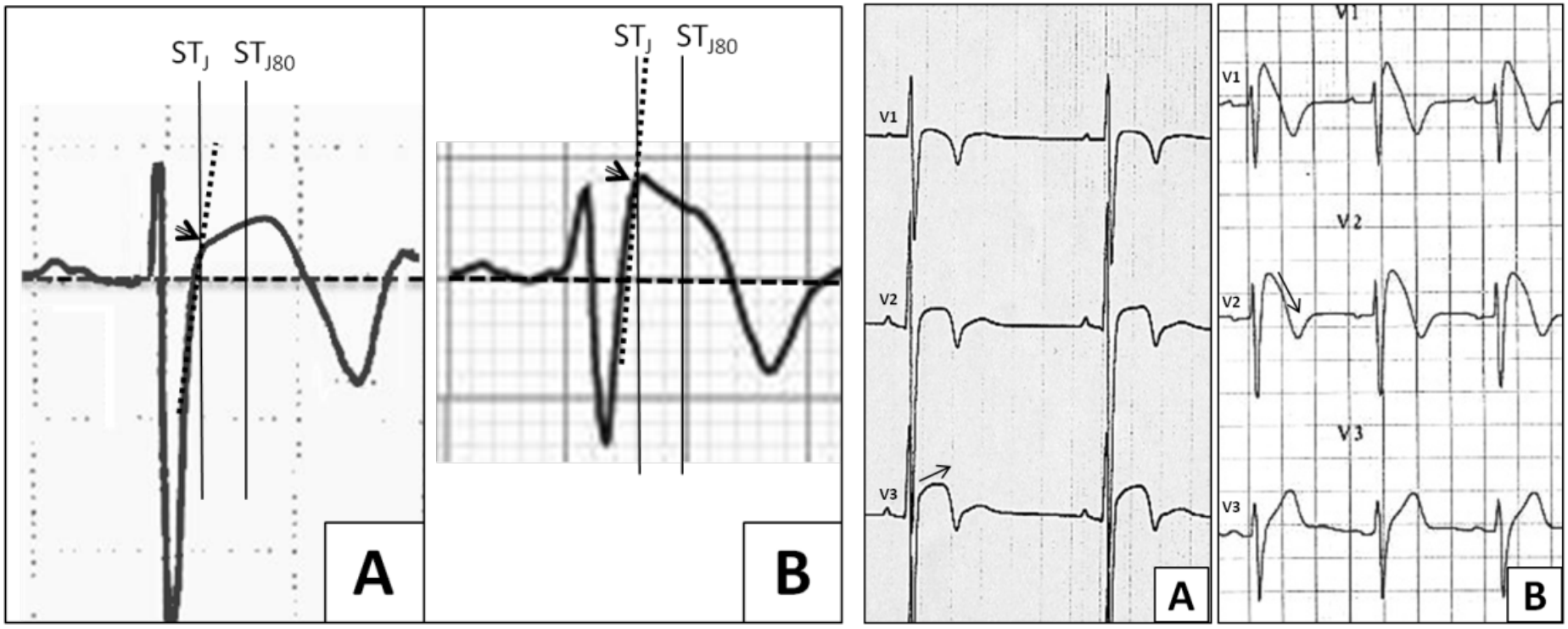

An up-sloping ST-segment configuration ($ST_J/ST_{80}<1$) showed a sensitivity of 97%, a specificity of 100% and a diagnostic accuracy of 98.7% for the diagnosis of ER

Zorzi A…Corrado D, Am J Cardiol 2015;115:529-532

European Heart Journal (2013) **34**, 3606–3609
doi:10.1093/eurheartj/eht458

EDITORIAL

Improving the interpretation of the athlete's electrocardiogram

Domenico Corrado*, Chiara Calore, Alessandro Zorzi, and Federico Migliore

Department of Cardiac, Thoracic, and Vascular Sciences, University of Padua, Italy

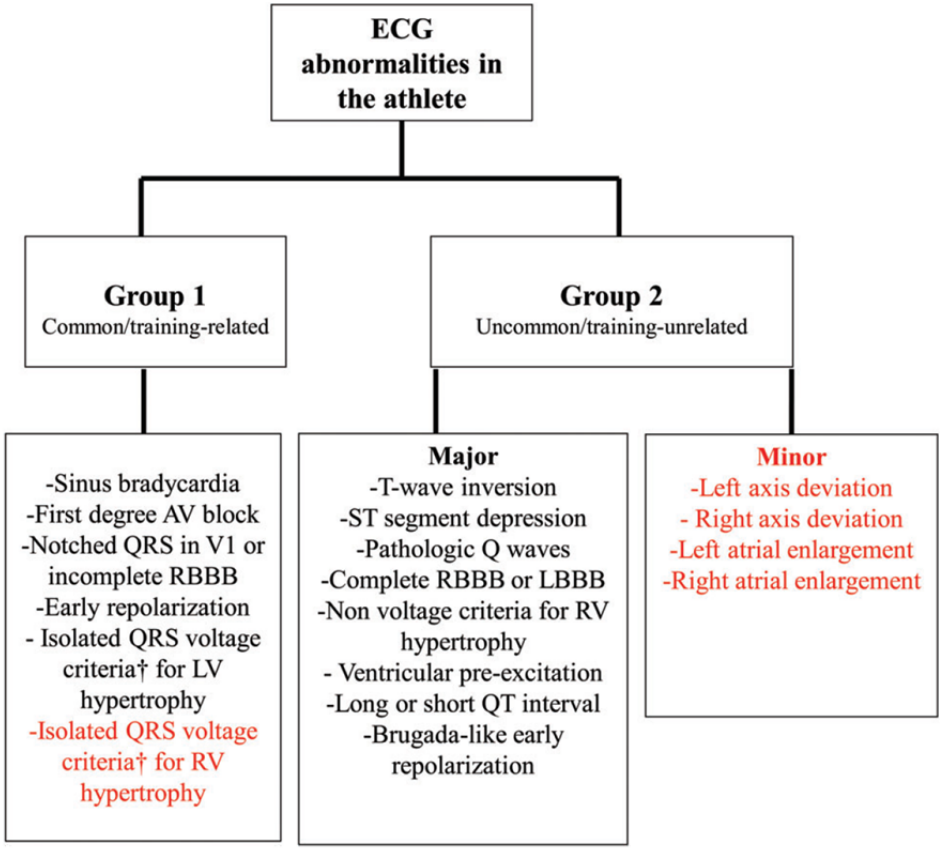

Figure 2 Proposed revision of criteria for electrocardiogram (ECG) interpretation in the athlete. Group 1 includes training-related ECG abnormalities which are more common in the athlete's heart than in cardiomyopathy. Uncommon and training-unrelated ECG abnormalities of Group 2 are divided into 'major', i.e. uncommon in the athlete's heart but frequent in cardiomyopathy, and 'minor', i.e. infrequent in both athletes and patients with cardiomyopathy (see text for further explanation). †Sokolow–Lyon voltage criteria. AV, atrioventricular; LBBB, left bundle branch block; LV, left ventricular; RBBB, right bundle branch block; RV, right ventricular.

Revised «Seattle Criteria» 2015

International Consensus Standards for ECG Interpretation in Athletes

Normal ECG Findings

- Increased QRS voltage for LVH or RVH
- Incomplete RBBB
- Early repolarization/ST segment elevation
- ST elevation followed by T wave inversion V1-V4 in black athletes
- T wave inversion V1-V3 ≤ age 16 years old
- Sinus bradycardia or arrhythmia
- Ectopic atrial or junctional rhythm
- 1° AV block
- Mobitz Type I 2° AV block

Borderline ECG Findings

- Left axis deviation
- Left atrial enlargement
- Right axis deviation
- Right atrial enlargement
- Complete RBBB

Abnormal ECG Findings

- T wave inversion
- ST segment depression
- Pathologic Q waves
- Complete LBBB
- QRS ≥ 140 ms duration
- Ventricular pre-excitation
- Prolonged QT interval
- Brugada Type 1 pattern
- Profound sinus bradycardia < 30 bpm
- PR interval ≥ 400 ms
- Mobitz Type II 2° AV block
- 3° AV block
- ≥ 2 PVCs
- Atrial tachyarrhythmias
- Ventricular arrhythmias

In isolation

2 or more

No further evaluation required
in asymptomatic athletes with no family history of inherited cardiac disease or SCD

Further evaluation required
to investigate for pathologic cardiovascular disorders associated with SCD in athletes

Conclusions

- Refinement of current ECG screening criteria has the potential to further reduce the burden of false positive ECGs in athletes
- In assessing the double-edged duality of ECG preparticipation screening – cost versus effectiveness- it is critical to consider that prevention is not about saving money, it is about saving lives

Appropriate interpretation of the athlete's electrocardiogram saves lives as well as money

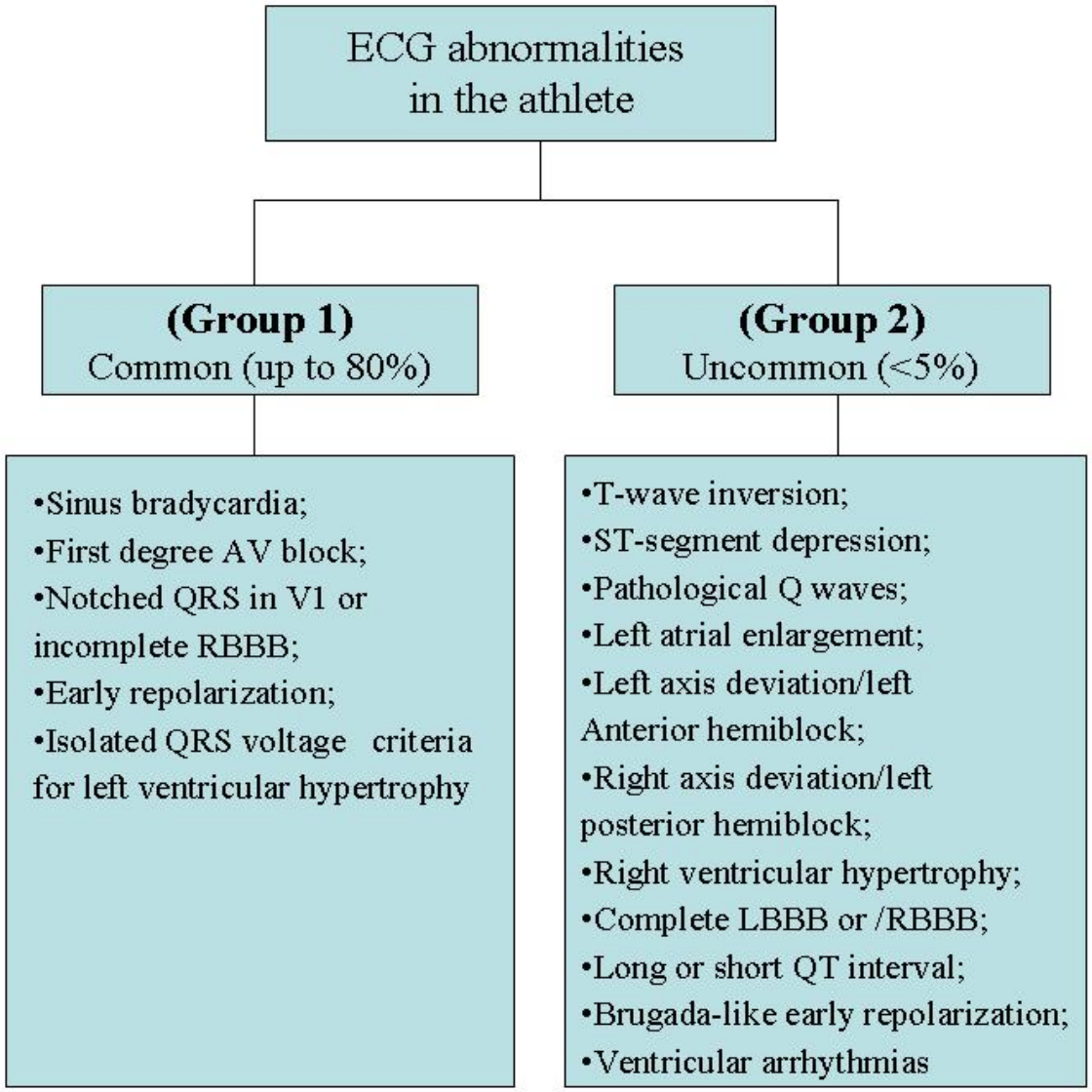

Corrado D, McKenna WJ. Eur Heart J 2007 ;28:1920-2